

P 1231: TREATMENT OF HEMANGIOMAS WITH 595NM PULSED DYE LASER DERMOBEAM

Jean-Loïc MICHEL*(Md): Private office of Dermatology, Postal address: Residence V° Avenue ; 14 place des Grenadiers-Quartier Grouchy, 42000 SAINT-ETIENNE, France. Tel.: +33.4.77.91.13.46. Fax: +33.4.77.91.13.48. E-mail: jean.loic.michel@wanadoo.fr

Introduction: All dye lasers permit treatment of Port-wine stains, which are classic indication of dye laser, while hemangiomas are scarcely treated. The third generation of dye laser emits at a wavelength of 595nm and offers best performance for treating hemangiomas. Hemangiomas represent the most common benign tumor of infancy, and ulceration is its most frequent complication (1). The comparison of hemangioma treatment by pumped dye laser (585nm) and frequency-doubled Nd:YAG (532nm) don't show any difference (2), but there is no report of treatment with a third generation pulsed dye laser (wavelength of 595nm) (3-6).

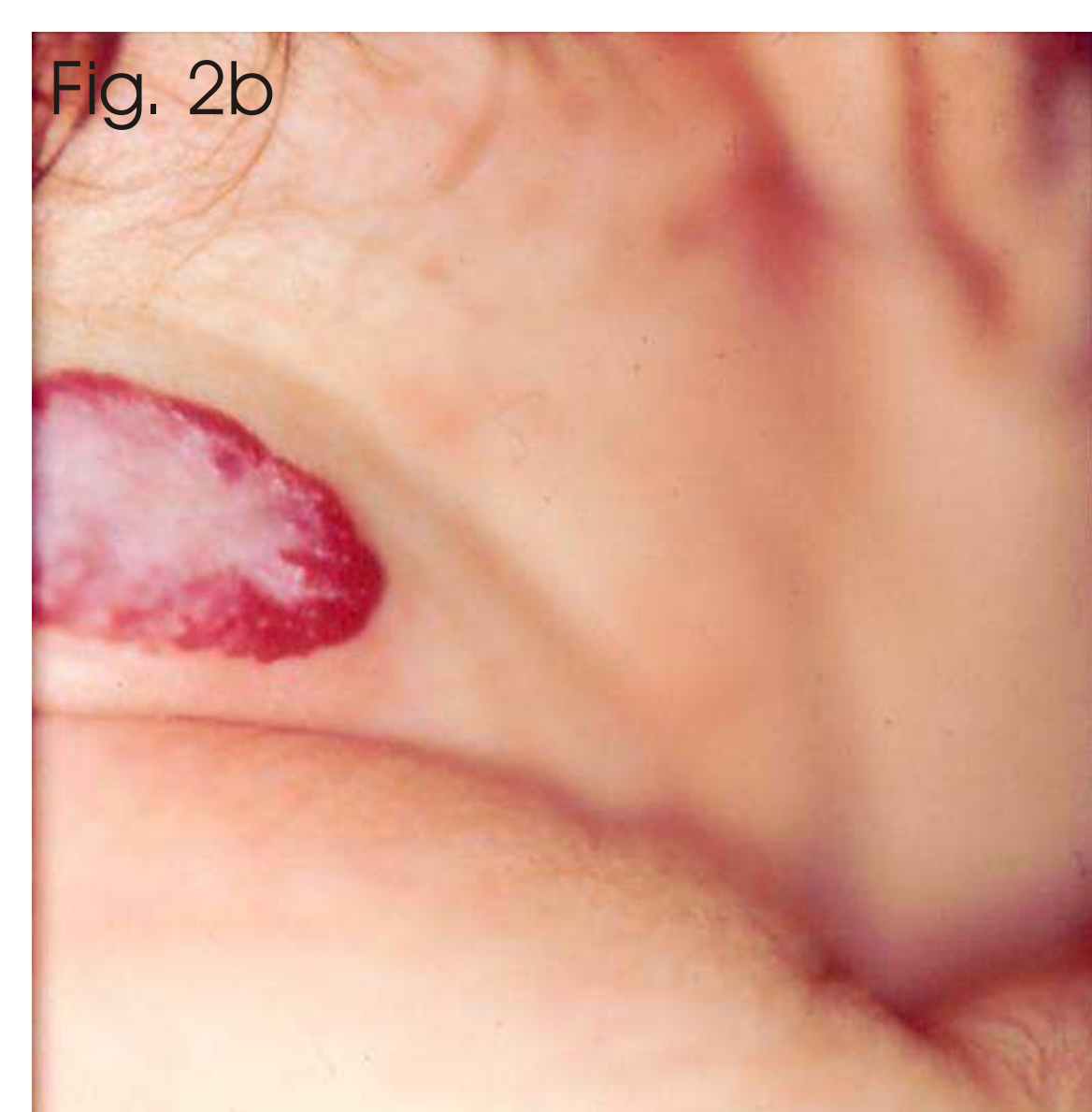
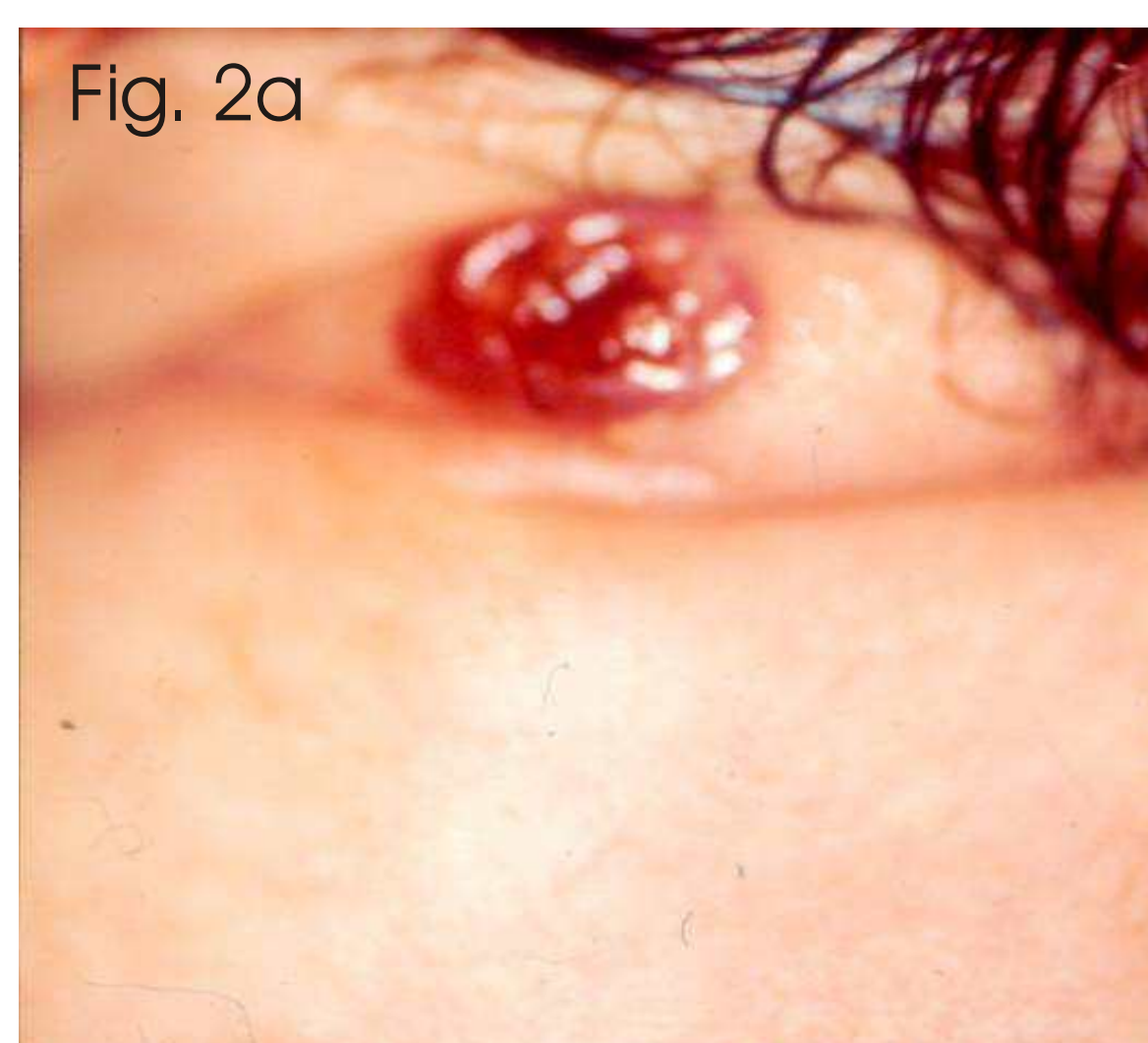

Fig 2 a,b: Patient number 4 (22/08/00 ; age at first treatment: 1 months/ female), localization : right occipital ; size of 22mm, only 1 session.

Results: We try to evaluate the therapeutic response of ulcerated hemangiomas to 595nm wavelength pulsed dye laser. We had no adverse effect; but 2 failures for excessive pain for ulcerated hemangiomas because of the importance of the subcutaneous component. The mixed hemangiomas remained unchanged. These 2 cases showed proliferation of the subcutaneous component, and need of general corticoids. We must see again the child about 10 to 15 days after the first treatment, to evaluate the residual pain and continue the treatment just up to cessation of pain (as early as the 1st session, in the majority of cases), and to healing over ulceration, which can be reached after 4 treatments (fig. 3 a-b).

Discussion: Hemangioma is an indication of laser therapy only in rare instance (1). For the refractory ulceration failing of healing after 2 weeks of specialized dressing, low fluence is available (2-5). For aesthetic risk localization, just like philtrum, columella, or nasal margin, you can use a 7mm spot size, 0.5 to 6ms pulse duration, and a fluence of 5 to 7J/cm². We can also treat residual telangiectasia.

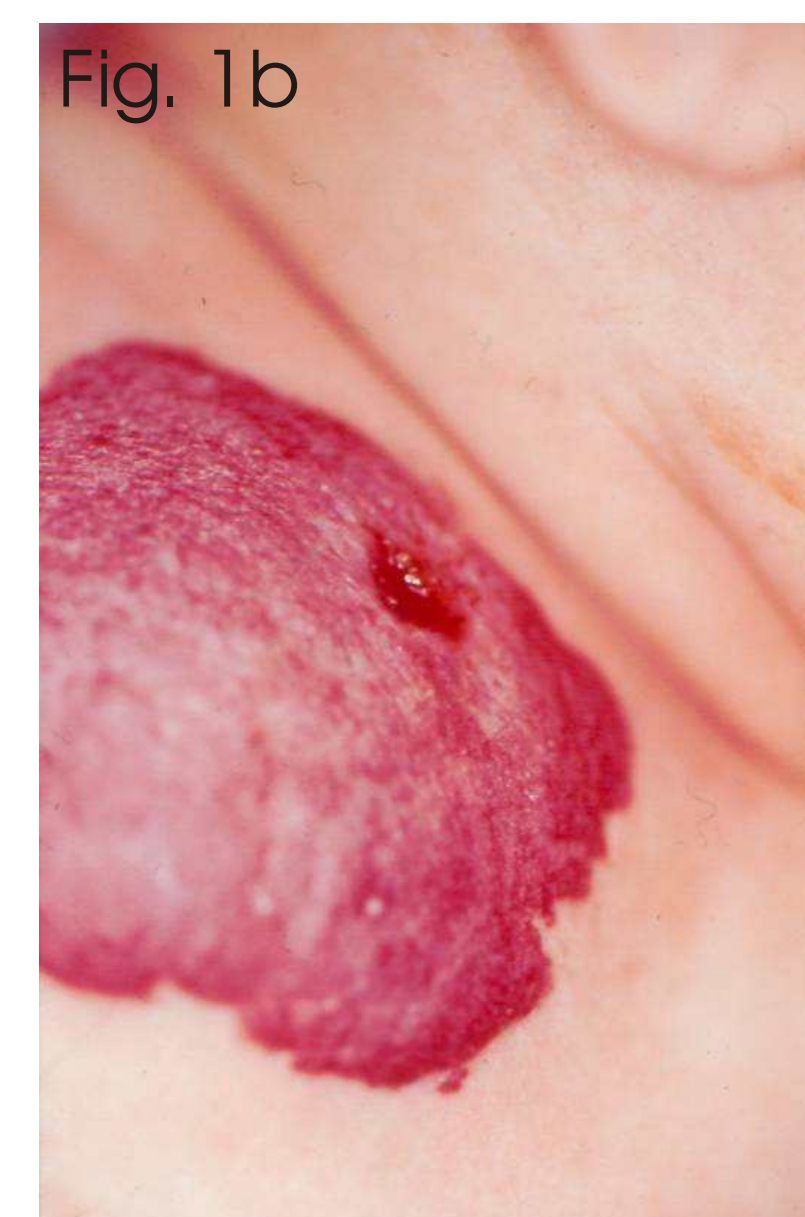
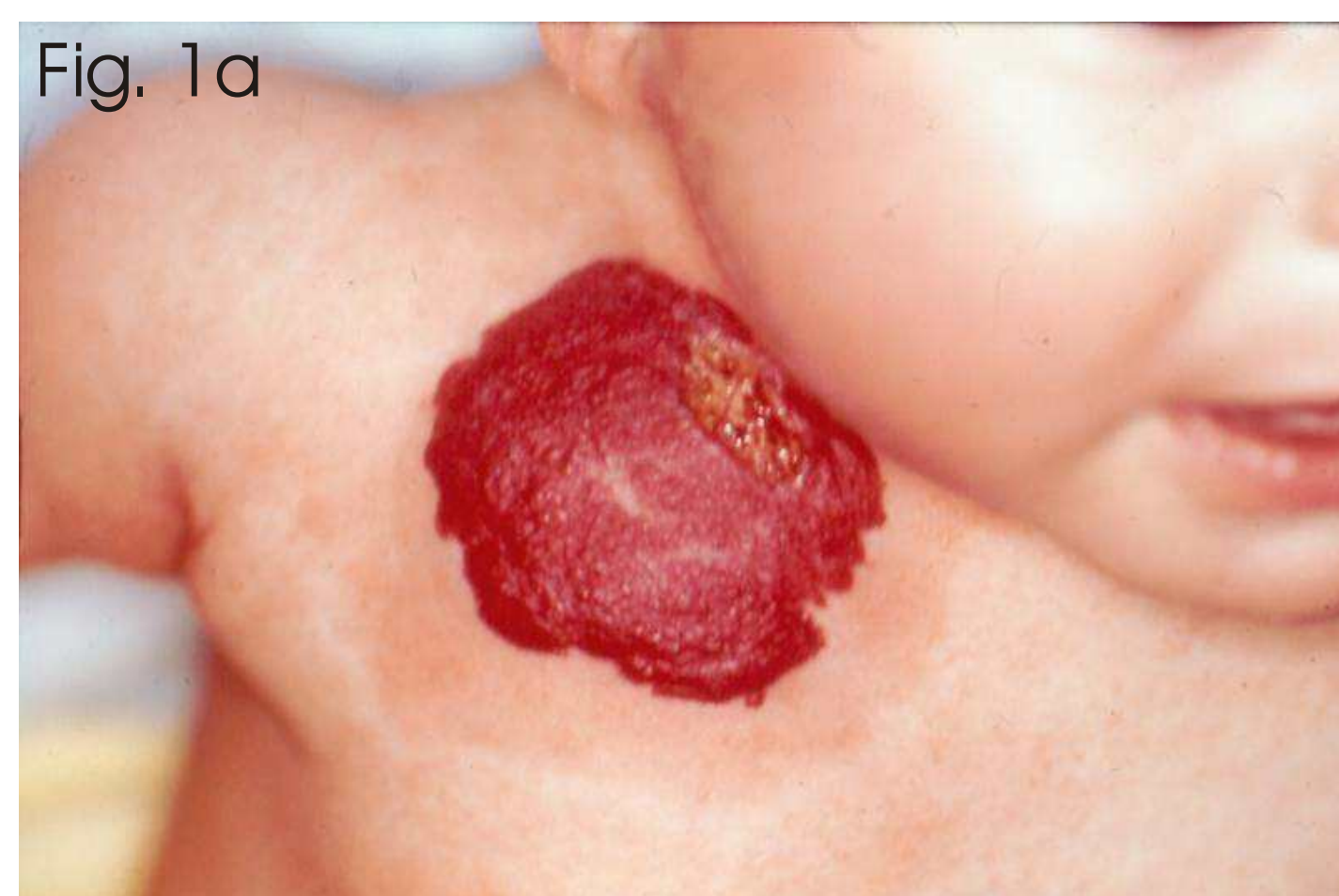
Fig 1a,b : Patient number 7 (22/11/00; age at first treatment: 2,5 months/ female), localization right shoulder; size of 38 mm, 2 sessions at 3 weeks intervals.

Material and methods: Our purpose was to review the therapeutic response of ulcerated hemangioma to the third generation pulsed dye laser. We have used a 595nm, Dermobeam 2000 (from DEKA M.E.L.A. Calenzano, Italy), that is equipped with a skin cooling system (Spray) (5). The Spot size was of 7mm, the energy density (fluence J/cm²) from 4 to 8J/cm². The emission modality (repetition rate) was repeated at 0.5Hz. Initially we have chosen a long pulse duration of 30ms, but in the majority of cases was of 0.5ms. The SmartSpray Cooling system parameters were: freezing flood duration and advance. The spray pulse length was from 60%. The delay (advance or anticipation) was of 10ms. The gas under pressure (tetrafluoroethane) is contained in a small metallic can. This synthetic ice is unflammable, and contents 200ml per bottle. A length of 100% (= 40l of freezing gas at one pulse), permits 5000 laser pulses for a safe delivery of higher energy fluences by cooling epidermis while leaving the vessels temperature unchanged. The consequent anesthetic effect is limiting the need for additional topical, local or general anesthetic. Generally, 10 to 30msec prior to each laser pulse are needed. This epidermal cooling minimizes the risk of adverse effects, such as hyperpigmentation (23% without cooling method), hypopigmentation, and scars. We have treated 11 children from 01/11/00 to 31/10/01 (during a 1 year period). We report 9 cases of ulcerated hemangioma, 2 with bleeding, and 1 for esthetical reason. The female/male sex ratio was around 3:1 (8 girls, and 3 boys). Patients were aged from 1 to 15 months, for a average of 4,9 months.

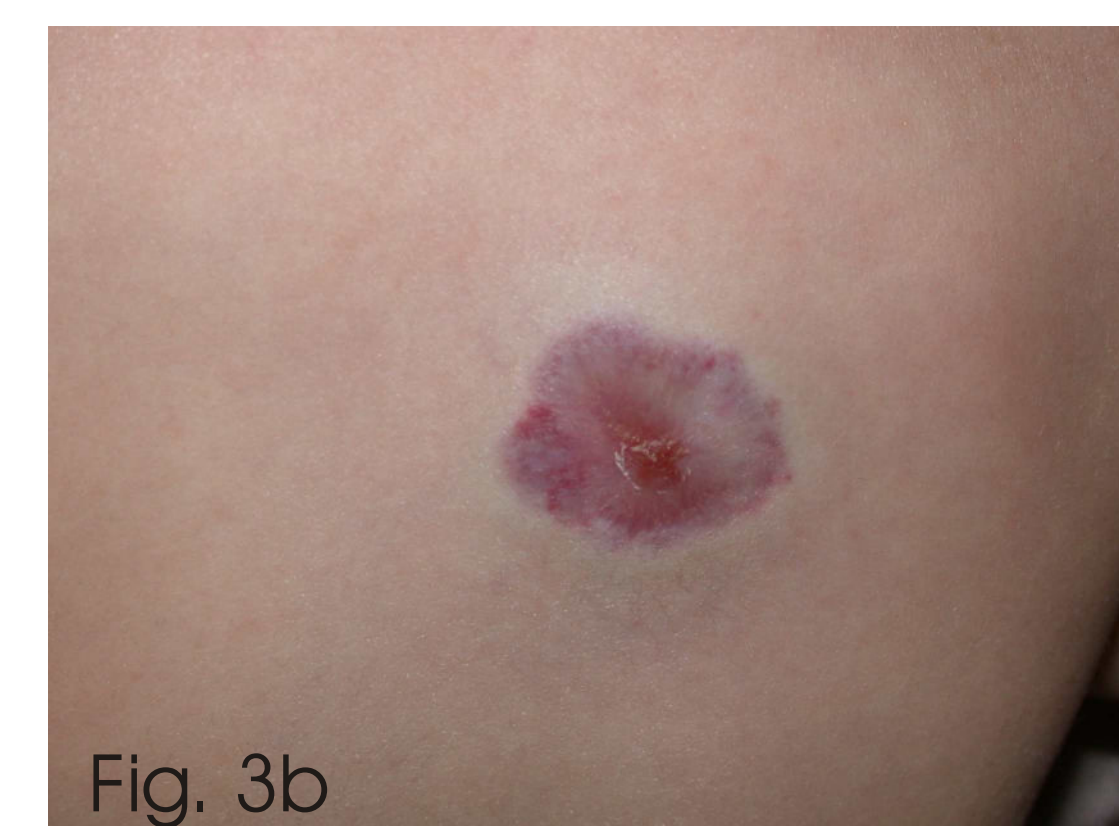
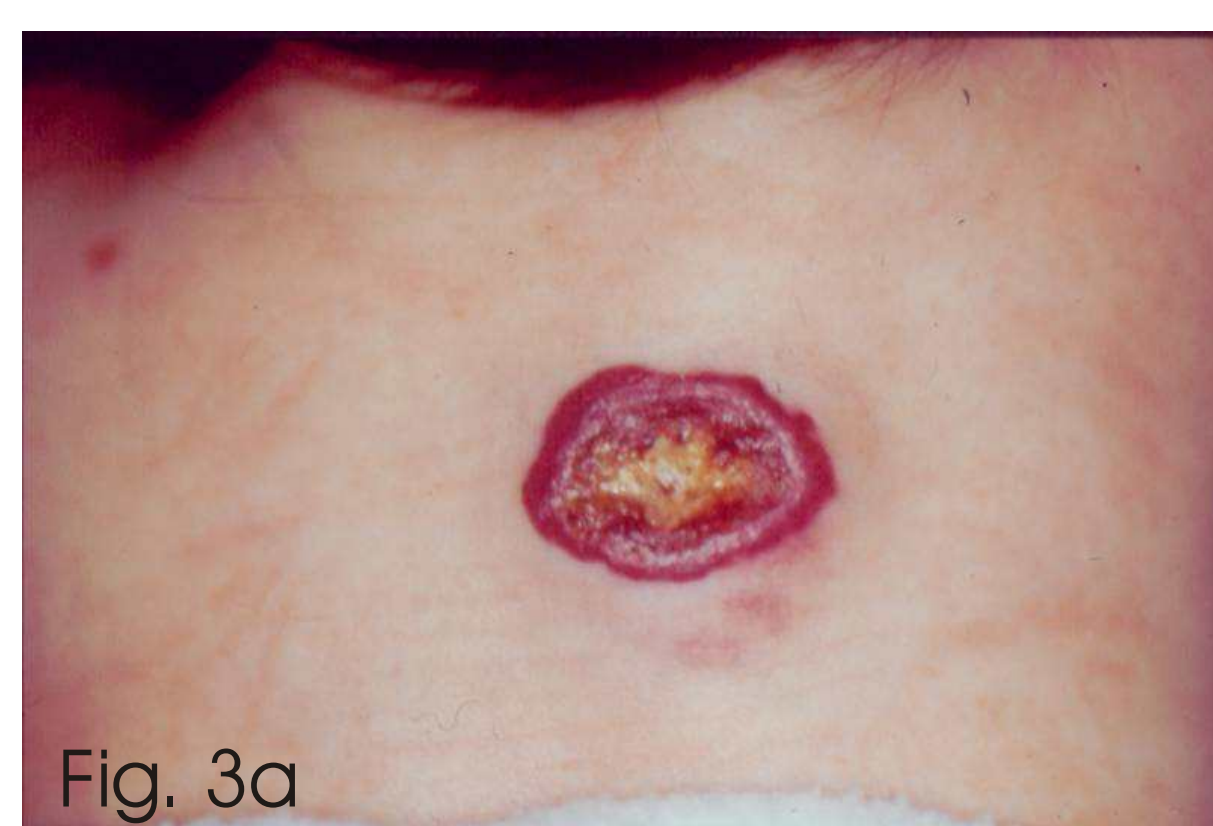
Fig 3 a,b: Patient number 6 (16/11/00; age at first treatment: 4 months, female), localization on back (scapular) ; size of 53mm, 4 sessions at 2 weeks to 2 months intervals.

Birth date/Age at treatment/ gender	Localization/size (mm)	Ulceration/pain	Number of session/intervall	Efficiency	Days	Fluence (J/cm ²)/spot size (mm)	Pulse duration (msec)
27/05/99; 15 months/M	Philtrum; 12	0/aesthetic indication	2 at 3 months	Yes	60	4/7	0,5
21/03/00; 7 months/F	buttock, 56X43	Yes/ ++	2/ general anesthesia	Yes	1	8/2	30
01/07/00; 9 months/M	Right forehead ;14/ diffuse neonatal hemangiomatosis	0/ bleedings	1	Yes	bleeding recurrence, surgery	5/7	0,5
22/08/00 ; 1 months/F	Right occipital ;22	Yes/ ++	1	Yes	1	8/2	30
15/09/00; 4 months/F	right buttock ; 44	Yes+/bleedings	1/ at 1 months no 2 nd TTT.	Yes		5,5/7	0,5
16/11/00; 4 months/F	back (scapular) ; 53	Yes/+++bleedings	4/ 2 weeks at 2 months	Yes/ regression	2	4-5,5/7	0,5
22/11/00; 2,5 months/F	Right shoulder ; 38	Yes/+++	2/ 3 weeks	Yes	1	6,5/7	0,5
13/04/01; 5 months/F	left Lumbar, 47X34	Yes/+++/ oozing	1/ subcutaneous component	Failure/ Systemic corticoids	Ulceration, oozing	6/7	0,5
25/01/01 ; 6 months/F	Right hand and wrist ; 63X41	Yes/+++necrosis	1/ subcutaneous component	Failure/ Systemic corticoids	pain, necrosis	6/7	0,5
28/05/01 ; 1,2months/F	Right of the neck, 20	Yes/+++/ bleedings	1	yes	1	6/7	0,5
11/06/01 ; 4 months/M	2 hemangiomas right internal canthus; 4 et 2	bleedings	2/ 1 weeks	yes		5/5	0,5

- References:**
- Kim HJ, Colombo M., Frieden IJ. Ulcerated hemangiomas : clinical characteristics and response to therapy. J. Am. Acad. Dermatol. 2001 ;44 :962-72.
 - Raulin C., Greve B. Retrospective clinical comparison of hemangioma treatment pumped (585 nm) and frequency-doubled Nd:YAG (532 nm). Laser Surg Med. 2001 ; 28 :40-43.
 - Poetke M., Philipp C., Berlien H.P. Flashlamp-pumped pulsed dye laser for hemangiomas in infancy. Arch. Dermatol. 2000 ;136 :628-32.
 - Hohenleutner S., Badur-Ganter E., Landthaler M., Hohenleutner U. Long term results in the treatment of childhood hemangioma with flashlamp-pumped pulsed dye laser: an evaluation of 617 cases. Laser Surg Med. 2001 ; 28 :273-77.
 - Chang CJ, Kelly KM, Nelson JS. Cryogen spray cooling and pulsed dye laser treatment of cutaneous hemangiomas. Ann Plast. Surg. 2001 ;46 :577-83.
 - Endo H., Kawada A., Aragane Y., Yamashita Y., Isogai R., Yodate T. The succesful treatment of diffuse neonatal hemangiomatosis with a flashlamp pulsed dye laser. Pediatr. Dermatol. 2001;18 (2):146-8.

Key Words: Hemangioma; pulsed dye laser, infancy.