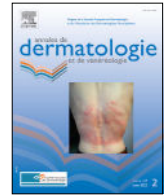




Available online at
ScienceDirect
www.sciencedirect.com

Elsevier Masson France
EM|consulte
www.em-consulte.com/en



Research letter

Long-pulsed Nd:YAG laser using an “in motion” setting to treat telangiectatic rosacea

D. Piccolo^a, I. Zalaudek^b, C. Genovesi^a, C. Dianzani^c, G. Crisman^a, I. Fusco^{d,*}, C. Conforti^b

^a Skin Centre – Dermal-Aesthetic Laser Centres, Avezzano, Pescara and L'Aquila, Italy

^b Department of Dermatology and Venereology, Dermatology Clinic, Maggiore Hospital, University of Trieste, Trieste, Italy

^c Plastic and Reconstructive Surgery Department, Dermatology Section, Campus Bio Medico, University of Rome, Rome, Italy

^d El.En. Group, 50041 Calenzano, Italy

ARTICLE INFO

Article history:

Received 11 March 2022

Accepted 28 September 2022

Available online xxxx

Keywords:

Telangiectatic rosacea

Long-pulsed Nd:YAG Laser

ABSTRACT

Background: Rosacea is an inflammatory condition of the face characterized in its early stages by flushing, erythema and telangiectasias.

Objectives: We evaluate the efficacy of long-pulsed Nd:YAG laser on erythematoustelangiectatic rosacea (ETR).

Methods: In a retrospective case study of 21 patients (14F, 7M) with an average age of 29 years (range 19–41), were treated with two sessions at a distance of one month, with phototype up to III (5 phototype I, 14 phototype II, 2 phototype III) with a fluence of 20 J/cm².

Results: We observed a reduction of the erythematous component between 50% and 80% after two sessions, with an average pain score attributed to the treatment, measured by visual analogue scale (VAS), of 3.

Conclusion: In this case series in which Nd:YAG laser had been used with a “in motion” technique, we observed a reduction of the side effects and pain.

© 2022 The Author(s). Published by Elsevier Masson SAS. This is an open access article under the CC BY-NC-ND license (<http://creativecommons.org/licenses/by-nc-nd/4.0/>).

In this retrospective case series, 21 patients (14F, 7M) with erythematous-telangiectatic rosacea (ETR) were treated using Nd:YAG laser (MoveoVL Deka Mela Sarl, Italy). The mean patient age was 29 years (range 19–41) and phototypes ranged between I and III (5 phototype I, 14 phototype II, 2 phototype III). Two sessions were performed at a one-month interval using a fluence of 20 J/cm² with 20 mm sapphire skin-cooling. The “in movement” technique uses the lowest possible energy output to minimise painful sensation. During the procedure, the operator moves the handpiece continuously in a slow linear/circular motion over an area of 100 cm² (equivalent to a cheek), making several passes back and forth until a defined total energy threshold is reached (typically within 2/3 passes). The emission frequency is set to a higher frequency than for the standard procedure (multiple pulses per second). Our clinical endpoint was the creation of mild erythema: medium redness associated with a slight sensation of heat, which normally subsides within a few minutes, as with the previous stationary technique (single pass). In our case series, we observed a reduction of between 50% and 80% in the erythematous

component after two sessions, with an average pain score of 3 on a visual analogue scale (VAS) (Fig. 1).

Rosacea is an inflammatory condition of the face characterized in its early stages by flushing, erythema, and telangiectasia. For this reason it is defined as erythematous-telangiectatic rosacea (ETR). Early treatment of vascular lesions limits exacerbation of the condition, while physical therapies such as lasers have shown excellent results in the management of telangiectasias [1]. However, the role of Nd:YAG laser on the erythematous component has not been widely studied. In fact, because the redness in patients with ETR is diffuse and there is no specific target, unlike telangiectasia, intensified pulsed light (IPL) is very often used but it produces discordant results [2]. More recently, however, Say et al. demonstrated excellent results in a study involving 66 patients presenting ETR treated with long-pulsed Nd:YAG laser using a spot size of 2–3 mm, fluence of 100–160 J/cm², and a pulse duration of 15–20 ms [3]. However, although stationary (single-pass) Nd:YAG laser treatment can cause side effects such as pain, burns and vesiculation, a multi-pass (“in motion”) technique can limit such side effects and ensure homogeneity of treatment. Use of this method enables gradual increase of temperature, monitoring of skin reactions, and discontinuation or modification of treatment at any time, thus minimizing the typical side effects associated

* Corresponding author.

E-mail address: i.fusco@deka.it (I. Fusco).

<https://doi.org/10.1016/j.annder.2022.09.007>

0151-9638/© 2022 The Author(s). Published by Elsevier Masson SAS.

This is an open access article under the CC BY-NC-ND license (<http://creativecommons.org/licenses/by-nc-nd/4.0/>).

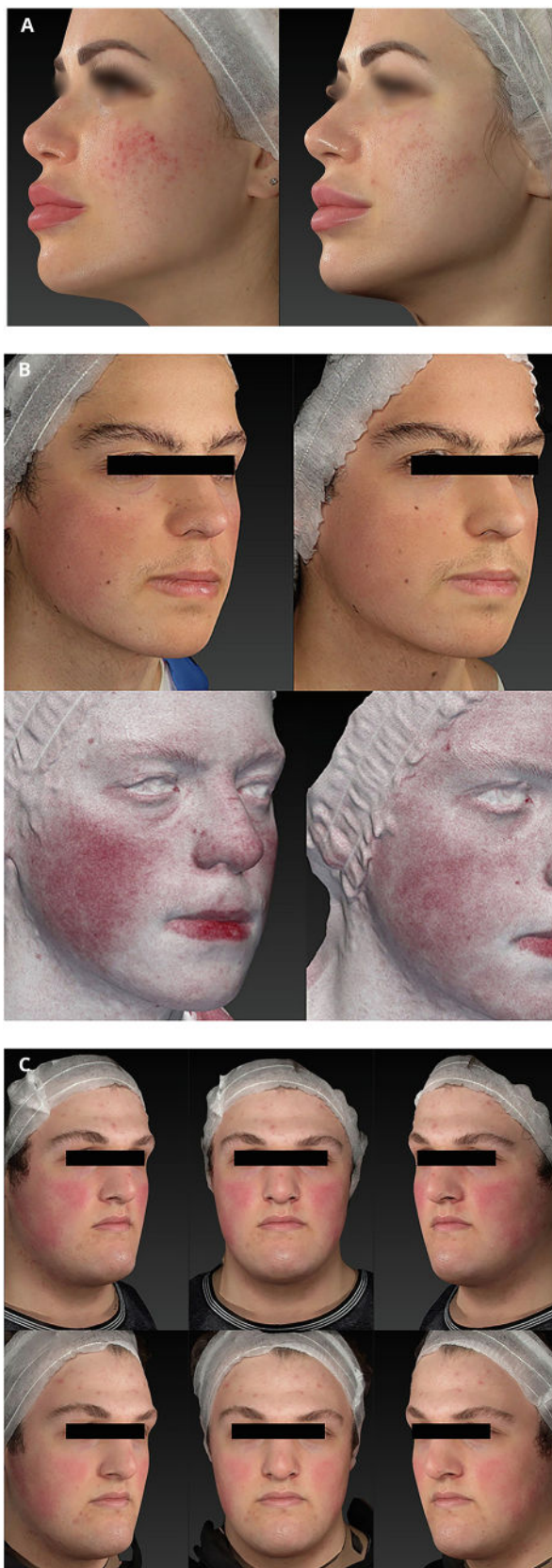

Fig. 1. Plates A, B and C show erythematous rosacea before (above) and after (below) treatment using the "in motion" technique.

with the traditional method. In this case series using Nd:YAG laser with an "in motion" technique, a reduction in side effects and pain was observed among treated patients. The limitation of our study is the small number of patients included. Our future goal is to increase the number of patients treated with evaluation of recurrence rates and disease-free intervals after two laser sessions.

Ethical approval

The article complies with the Declaration of Helsinki on the ethical principles for medical research involving human subjects.

Conflict of Interest

I. Fusco is employed at El.En. Group.
The other authors: none.

Acknowledgment

All patients in this study provided written informed consent for publication of their case details.

References

- [1] Del Rosso JQ, Tangheiti E, Webster G, et al. Update on the management of rosacea from the American Acne & Rosacea Society (AARS). *J Clin Aesthet Dermatol* 2020;13:17–24.
- [2] Kassir R, Kolluru A, Kassir M. Intense pulsed light for the treatment of rosacea and telangiectasias. *J Cosmet Laser Ther* 2011;13:216–22.
- [3] Say EM, Okan G, Gökdemir G. Treatment outcomes of long-pulsed Nd: YAG Laser for two different subtypes of rosacea. *J Clin Aesthet Dermatol* 2015;8:16–20.