

# Successful Treatment of Reticular Blue Veins of the Lower Eyelid by Long-Pulse Nd: YAG – Case Report with 8-Year Follow-Up

Alberto Goldman<sup>1</sup>, Torello Lotti<sup>2</sup>, Georgi Tchernev<sup>3,4</sup>, Uwe Wollina<sup>5\*</sup>

<sup>1</sup>*Clinica Goldman, - Plastic Surgery, Porto Alegre/RS, Brazil;* <sup>2</sup>*Università Degli Studi "G. Marconi", Rome, Italy;* <sup>3</sup>*Medical Institute of Ministry of Interior (MVR), Department of Dermatology, Venereology and Dermatologic Surgery, Sofia, Bulgaria;* <sup>4</sup>*Onkodermat - Polyclinic for Dermatology and Dermatologic Surgery, Sofia, Bulgaria;* <sup>5</sup>*Städtisches Klinikum Dresden, Department of Dermatology and Allergology, 01067 Dresden, Germany*

## Abstract

**BACKGROUND:** Facial reticular blue veins are of esthetic concern. Most often these veins develop on the lower lids. The safest and most effective way of treatment is by vascular lasers.

**CASE REPORT:** We report on a successful reticular vein treatment using a long-pulsed 1064 nm Nd: YAG laser. We present a follow-up of 8 years with constant esthetic improvement without unwanted adverse events.

**CONCLUSION:** There was no relapse demonstrating the efficacy of Nd: YAG laser.

**Citation:** Goldman A, Lotti T, Tchernev G, Wollina U. Successful Treatment of Reticular Blue Veins of the Lower Eyelid by Long-Pulse Nd: YAG – Case Report with 8-Year Follow-Up. Open Access Maced J Med Sci. 2018 Jan 25; 6(1):58-60. <https://doi.org/10.3889/oamjms.2018.021>

**Keywords:** Facial esthetics; Reticular facial veins; Periocular rejuvenation; Nd: YAG laser; Treatment

**\*Correspondence:** Uwe Wollina. Städtisches Klinikum Dresden, Department of Dermatology and Allergology, 01067 Dresden, Germany. E-mail: [wollina-uw@khdf.de](mailto:wollina-uw@khdf.de)

**Received:** 29-Jul-2017; **Revised:** 11-Nov-2017; **Accepted:** 29-Oct-2017; **Online first:** 31-Dec-2017

**Copyright:** © 2018 Alberto Goldman, Torello Lotti, Georgi Tchernev, Uwe Wollina. This is an open-access article distributed under the terms of the Creative Commons Attribution-NonCommercial 4.0 International License (CC BY-NC 4.0)

**Funding:** This research did not receive any financial support

**Competing Interests:** The authors have declared that no competing interests exist

## Introduction

Superficial and visible veins in the face can represent an aesthetic concern. Reticular blue veins occur most frequently in the lower eyelids toward the lateral portion of the orbit. These vascular structures around the eyelids are more visible because of the specific anatomical characteristics of the region with no or limited subcutaneous fat beneath the thin skin. They become more visible in patients with fair skin, after weight loss and during ageing. The veins are asymptomatic and the main concern is related to the aesthetic aspect. The desire of the patient is to eliminate the appearance of these dilated and protruding reticular veins. The management of periorbital veins is part of periorbital rejuvenation [1].

Despite all risks and side effects sclerotherapy using sodium tetradecyl sulfate, transection and cautery, extraction (phlebectomy) and

electro cauterization remained during a long time the main treatment options [2]. The safety profile of certain techniques, such as sclerotherapy, is questionable in this region where complications related to vision would be catastrophic. Currently, the most effective and safe method for treating these cosmetically unattractive veins in the periocular region is the laser [3].

## Case report

We present a case of a 41-year-old female patient with a reticular vein in the lower lid (blue periocular lower eyelid vein, patient skin photo type Fitzpatrick II) (Fig. 1 a, b). No previous treatment was done. After a clinical examination, she was treated with three consecutive sessions of laser. The

parameters of the long-pulsed 1064 nm neodymium-doped yttrium aluminium garnet (Nd: YAG) laser were as follows: fluence ranging from 100 to 125 J/cm<sup>2</sup> with a 2.5 mm and 4.0 mm spot size. The pulse width ranged from 3 msec to 15 msec (Synchro and Smartepil, Deka, Italy).

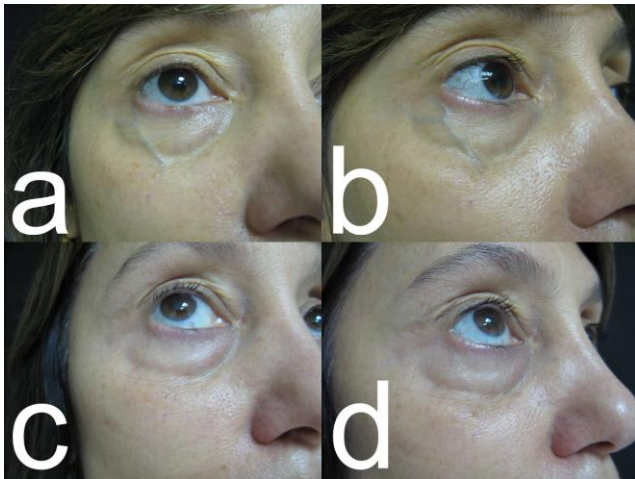


Figure 1: a, b - Reticular vein in lower eyelid; c, d Result 8 years after laser treatment

The sessions were performed monthly. No topical or local anaesthesia was used. The eyes were protected with specific eye wear. Cryogen spray was used before and immediately after laser shot. Erythema and mild oedema occurred. No other side effects were observed. The vein was effectively treated and absorbed after the third session.

The patient was satisfied with the result and returned for consultation 8 years later for another reason (Fig. 1 c, d). The affected region previously treated with the laser presented no skin pigmentation and no evidence of reticular vein recurrence.

## Discussion

Laser treatment of vascular structures is dependent on the selected wavelength. The pulse width of the laser must be shorter than the target's thermal relaxation time, which is the time required for the target to lose half of its peak temperature following irradiation. And finally, the fluence has to be sufficient to achieve the desired tissue response within an appropriate time interval [4].

Laser treatment of facial veins or telangiectasia has been reported with different sources of laser including the diode, potassium titanyl phosphate (KTP), copper-bromide, Nd: YAG lasers and pulsed dye lasers among other. Treatment aims to achieve blanching without causing a skin or burn lesion with a consequent resorption of the vein

[5][6][7].

Thread-like constriction is the desired treatment endpoint of the vascular laser. This is a consequence of complete vascular occlusion by a thrombus. Cavitation can cause haemorrhage when a thrombus fails to occlude the vessel completely [8]. In vitro experiment found that vessel constriction was due to the constriction of thrombus induced by laser irradiation. The theoretical investigation revealed that the mechanism for the effective reduction of energy density by multi-pulse Nd: YAG laser was due to enhanced light absorption of the blood with thrombus formation [9][10].

The long-pulsed Nd: YAG laser at 1064nm demonstrated to be a safe, simple, effective and fast treatment in the treatment of superficial vein in the eyelid [11][12][13]. Eremia and Li (2002) were the first who reported on Nd: YAG laser in 8 patients with periorbital reticular veins. Their treatment parameters consisted of a fluence between 125-150 J/cm<sup>2</sup> with a 6 mm spot size and pulse widths of 75-100 msec. They also employed cryogen spray like us. However, they did not report on the long-term outcome.

We used a smaller spot size of 4 mm with a much shorter pulse width between 3 to 15 msec. This has been recommended based on mathematical modelling of vascular response to laser irradiation. In general, for selective photothermolysis the laser pulse duration should be similar to the thermal relaxation time of targeted vessels (Anderson & Parrish 1983). For vessels with a diameter between 30 µm and 300 µm, a relaxation time between 1 to 100 msec has been calculated (Mordon & Bourgh-Heckly 2016) [14].

Here we report on the successful treatment of lower lid vein with a follow-up of 8 years. There was no relapse demonstrating the efficacy of Nd: YAG laser.

## References

1. Tan KS, Oh S-R, Priel A, Korn BS, Kikkawa DO. Surgical anatomy of the forehead, eyelids, and midface for the aesthetic surgeon. Massry GG, Murphy MR, Azizzadeh B (eds.) Master Techniques in Blepharoplasty and Periorbital Rejuvenation. New York: Springer Science+Business Media LLC, 2011: 11-24. [https://doi.org/10.1007/978-1-4614-0067-7\\_2](https://doi.org/10.1007/978-1-4614-0067-7_2)
2. Weiss RA, Ramelet AA. Removal of blue periocular lower eyelid veins by ambulatory phlebectomy. *Dermatol Surg.* 2002; 28(1):43-5. PMID:11991269
3. Chauhan N, Ellis DA. Periorbital rejuvenation: reticular vein treatment. *Facial Plast Surg Clin North Am.* 2013; 21(1):147-55. <https://doi.org/10.1016/j.fsc.2012.11.006> PMID:23369597
4. Anderson RR, Parrish JA. Selective photothermolysis: precise microsurgery by selective absorption of pulsed radiation. *Science.* 1983; 220(4596):524-7. <https://doi.org/10.1126/science.6836297>
5. Wollina U. Three hundred patients treated with ultrapulsed 980 nm diode laser for skin disorders. *Indian J Dermatol.* 2016; 61(5):540-4. <https://doi.org/10.4103/0019-5154.190111> PMID:27688445 PMCID:PMC5029241

6. Owen WR, Hoppe E. Copper bromide laser for facial telangiectasia: a dose response evaluation. *Australas J Dermatol.* 2012; 53(4):281-4. <https://doi.org/10.1111/j.1440-0960.2012.00948.x> PMID:23013144
7. Hare McCoppin HH, Goldberg DJ. Laser treatment of facial telangiectases: an update. *Dermatol Surg.* 2010; 36(8):1221-30. <https://doi.org/10.1111/j.1524-4725.2010.01613.x> PMID:20666808
8. Astafyeva LG, Gade R, Schmidt W-D, Ledneva G-P, Wollina U. Laser heating of biological tissue with blood vessels: Modeling and clinical trials. *Optics Spectroscopy.* 2006; 100(5):789–96. <https://doi.org/10.1134/S0030400X06050213>
9. Li D, Chen B, Wang G-X. Computational investigation on thermal responses of blood vessels during laser treatment of port wine stain. *Int J Numerical Methods for Heat and Fluid Flow.* 2016; 26(2):534-55. <https://doi.org/10.1108/HFF-03-2015-0084>
10. Li D, Li R, Jia H, Chen B, Wu W, Ying Z. Experimental and numerical investigation on the transient vascular thermal response to multi-pulse Nd:YAG laser. *Lasers Surg Med.* 2017; 49(9):852-865. <https://doi.org/10.1002/lsm.22695> PMID:28598555
11. Eremia S, Li CY. Treatment of face veins with a cryogen spray variable pulse width 1064 nm Nd:YAG Laser: a prospective study of 17 patients. *Dermatol Surg.* 2002; 28(3):244-7. PMID:11896777
12. Lai SW, Goldman MP. Treatment of facial reticular veins with dynamically cooled, variable spot-sized 1064 nm Nd:YAG laser. *J Cosmet Dermatol.* 2007; 6(1):6-8. <https://doi.org/10.1111/j.1473-2165.2007.00256.x> PMID:17348988
13. Chen DL, Cohen JL. Treatment of periorbital veins with long-pulse Nd:YAG laser. *J Drugs Dermatol.* 2015; 14(11):1360-2. PMID:26580889
14. Mordon S, Bourg-Heckly G. Laser dermatology. In: André P, Hanecke E, Marini L, Roland Payne C (eds), *Cosmetic Medicine & Surgery.* Boca Raton/ FL: CRC Press, 2016:341-55. <https://doi.org/10.1201/9781315382364-35>