Fractionated Carbon Dioxide Laser Treatment of Photoaging: Prospective Study in 45 Patients and Review of the Literature

Emily P. Tierney, MD,*† and C. William Hanke, MD, MPH†

BACKGROUND Ablative fractional photothermolysis (AFP) has been reported to be effective for photoaging.

OBJECTIVE To perform a clinical trial in 45 patients with moderate to severe skin photoaging to quantify improvement with AFP.

MATERIALS AND METHODS A prospective, single-blind study in 45 patients who presented for desired treatment of photoaging. Patients received a series of two to three treatments with AFP.

RESULTS Thirty-nine women (86.7%) and six men (13.3%) were enrolled. Patients received two or three treatment sessions (mean 2.4). There were no incidence of adverse events of scarring, prolonged erythema (lasting more than 7 days), postinflammatory hyper- or hypopigmentation, or infection in the 108 treatment sessions given during this study. Mean improvement was 48.5% (95% confidence interval (CI) = 44.6–52.4%) for skin texture, 50.3% (95% CI = 46.1–54.5%) for skin laxity, 53.9% (95% CI = 49.5–58.5%) for dyschromia, and 52.4% (95% CI = 47.9–56.9%) for overall cosmetic outcome (all $p < .05$).

CONCLUSIONS Significant improvement in photoaging of the face can be achieved using an AFP device with skin types I to III after a series of two to three treatments.

The authors have indicated no significant interest with commercial supporters.

Background

For nearly 15 years, the carbon dioxide (CO_2) laser has been the criterion standard treatment for skin resurfacing. Despite its superiority in the treatment of rhytides,[1–3] photodamage,[4,5] and acne scars,[6,7] the CO_2 laser has fallen out of favor in recent years because of the lengthy recovery period required after treatment and the high reported incidence of serious side effects, including scarring and delayed-onset hypopigmentation.

The avoidance of scarring, hypopigmentation, and lengthy recovery periods is a major factor behind the development and rising popularity of newer nonablative lasers.[8–16] These nonablative lasers generally target the dermis and attempt to stimulate dermal remodeling while avoiding epidermal injury and prolonged healing times.[8–16] Although safe, these devices are unable to generate the significant dermal coagulation seen with traditional CO_2 and erbium-doped yttrium aluminum garnet (Er:YAG) ablative laser resurfacing.[12]

The concept of fractional photothermolysis (FP)[17] revolutionized laser surgery by enabling the delivery of dermal coagulative injury without confluent epidermal damage, decreasing the risks of scarring and the extensive downtime after traditional ablative resurfacing. FP is based on the scientific concept of creating microscopic thermal wounds deep to the surface of the skin, which allows for faster wound healing and greater tissue contraction.[17,18] The concept of FP is to drill microscopic holes into the dermis in a grid pattern.[17–19] The analogy of FP often described is that of aerating a lawn.[19] The "lawn plugs," termed microscopic epidermal necrotic debris (MENDs), remain and are expelled through transepidermal elimination mechanisms over 7 to 10 days.[19] The consequences are twofold;

*Department of Dermatology, School of Medicine, Tufts University, Boston, Massachusetts; †Laser and Skin Surgery Center of Indiana, Carmel, Indiana

© 2011 by the American Society for Dermatologic Surgery, Inc. • Published by Wiley Periodicals, Inc. •
ISSN: 1076-0512 • Dermatol Surg ;37:1279–1290 • DOI: 10.1111/j.1524-4725.2011.02082.x

dermal conditions that have been approached indirectly in the past using epidermal wounding are now directly wounded as portions of the normal dermis are removed, and the remaining adjacent intact dermis and epidermis allow for rapid healing without relying on the presence of multiple adnexal structures.[19]

In the original studies of their prototype nonablative FP (NAFP) device, Manstein and colleagues[17] described the effects of FP in tissue contraction in periorbital skin. Tissue tightening and clinical improvement of periorbital rhytides was observed, byt results were limited to 2.9% linear shrinkage, correlating with a 19% clinical improvement in periorbital rhytides.[17]

In 2007, Hantash and colleagues[20] first described the use of an "ablative" CO_2 fractional resurfacing device (AFP), which produces an array of microthermal zones (MTZs) of a customizable density and depth with a confluent pattern of ablation and coagulation extending from the stratum corneum through the dermis.[20] In the initial in vivo studies demonstrating the histologic and clinical effects of this device, Hantash and colleagues confirmed with immunohistochemistry that persistent collagen remodeling occurred for at least 3 months after treatment.[20]

AFP, creating confluent columns of thermal injury in a random array extending from the stratum corneum to the reticular dermis, has demonstrated significant effects on skin tightening and texture beyond that seen with the original generation of NAFP devices.[20–29]

The safety profile seen with AFP marks a significant advantage over the traditional ablative resurfacing devices that is associated with prolonged postoperative erythema and risk of postinflammatory pigmentary change and scarring.[20–29] After full-face resurfacing with AFP, complete re-epithelialization is generally seen in 3 to 6 days.[20–28] This is in stark contrast to the 2 to 3 weeks of recovery after full-face resurfacing using traditional CO_2 laser systems.[1–16] Rapid re-epithelialization after AFP treatment results in few infections, which are further reduced with the use of prophylactic antiviral and antibiotic therapy. Faster re-epithelialization also results in patients requiring fewer days of occlusive ointment application, which greatly reduces the rate of acneiform eruptions, which are seen in up to 83% of patients treated using traditional CO_2 lasers.[16] Erythema, an expected side effect after treatment, also resolves much more quickly after AFR[20–29] than with traditional ablative CO_2 laser treatments, with which postoperative erythema persists for up to 3 to 4 months after treatment.[1–16]

We set out to perform a clinical trial in a series of 45 patients with moderate to severe skin signs of photoaging to quantify the degree of improvement in pigmentary and textural improvements with AFP. Given our preliminary work demonstrating the safety and efficacy of AFP on the neck,[26,29] all patients were treated at moderate to long pulse durations (1,000-1,500 μs) with the goal of optimizing improvements in skin texture and laxity in addition to dyschromia.

Materials and Methods

The study protocol conformed to the guidelines of the 1975 Declaration of Helsinki and was approved by the St. Vincent Hospital Institutional Review Board and Ethics Committee, Indianapolis, Indiana. Informed consent was obtained from all patients before enrollment. All patients were required to be available for longitudinal study over the course of the 6 to -18 months of treatment and post-treatment evaluation. This period involved a preoperative evaluation and 1-week and 3-month post-treatment visits.

We performed a prospective, single-blind study in 45 patients presenting to our office for desired treatment of facial signs of photoaging (dyschromia, rhytides, skin laxity, skin roughness, and creping) between July 2008 and December 2008. Patients were excluded from the study if they had active

infections, current pregnancy, a history of isotretinoin use in the year before laser treatment, a history of keloid scarring, known allergy to topical lidocaine anesthetic, or any cosmetic procedure in the area(s) of treatment in the 12 months before the study. Patients were given prophylactic treatment for herpes labialis with valacyclovir 1 g twice a day for 4 days after treatment.

The treatment area was thoroughly cleansed before the procedure using a gentle skin cleanser. A bupivacaine/lidocaine/tetracaine topical local anesthetic mix was applied 30 minutes before treatment. Treatment was administered to the face using SmartXide Dermal Optical Thermolysis (DOT, DEKA, Calenzano, Italy), an ablative fractionated CO2 laser (10,600 nm) at settings of 30 W and 500 μm pitch for 1,000 to 1,500 μs. Forced cold air was administered during treatment for anesthesia using the Zimmer Cooler device (LaserMed, Shelton, CT) at a setting of 5. This machine uses a compressor system with a flow of 500 to 1,000 L/min and a temperature as low as − 30 ° C, depending on the desired cooling level (range 1–6) with the handpiece held between 2 and 3 inches from the patient's skin. The air nozzle was held off to the side of the area being treated, and the cool air beam was delivered to the skin at an angle approximately 90° to the direction of movement of the laser handpiece.

Patients received a series of two to three treatment sessions at 8-week intervals. The degree of clinical improvement with treatment determined the number of treatment sessions.

Six months after the final treatment, physician evaluation of photographs was done to assess the degree of improvement in four clinical indicators: skin texture, skin laxity, individual rhytides, and overall cosmetic outcome. Each of the clinical indicators was evaluated on a quantitative photoaging scale (Table 1) based on the scale designed by Alexiades-Armenakas[12] and modified by our group to apply to changes in photoaging after AFP treatment. In addition, the degree of improvement was calculated as percentage improvement between the initial treatment and the final visit 6 months after the final treatment.

Statistical Analysis

For each patient, the pretreatment and post-treatment scores for each category were recorded, as were treatment number and final date of follow-up. Pretreatment scores were recorded at baseline on the date of the first treatment. Post-treatment scores were recorded on the date of final follow-up.

Percentage change in score was calculated as the score difference divided by the baseline score. For each category (dyschromia, skin texture, skin laxity, and overall cosmetic outcome), the absolute score change, raw percentage change, mean percentage change, and 95% confidence interval (CI) were calculated.

The paired *t*-test was used to test change in each clinical indicator score (skin texture, skin laxity, individual rhytides, and overall cosmetic outcome) from baseline to 6 months after treatment. $P < .05$ was considered statistically significant.

Results

Forty-five patients with moderate to severe photoaging (39 women, 86.7%; 6 men, 13.3%) were treated using an ablative fractional photothermolysis device (DOT Laser, DEKA, Calenzano, Italy) (Table 2). Patients ranged in age from 45 to 75 (mean 58.5). The patients were Fitzpatrick skin types I to III: 26.7% Fitzpatrick skin type I, 60.0% Fitzpatrick skin type II, and 13.3% Fitzpatrick skin type III. Patients received two or three treatment sessions (mean 2.4). The results of 108 treatment sessions were included in the results of the study.

Post-treatment side effects included pinpoint bleeding (lasting 24–48 hours), edema (lasting 48–72 hours), diffuse severe erythema (lasting 24–72 hours), moderate erythema that could be concealed

TABLE 1. Photoaging Scale*

Grading Scale	*Descriptive parameter*	*Dyschromia*	*Laxity*	*Texture*
0	None	None	None	None
0.5	Minimal	Few (1–3) discrete small (<5 mm) lentigines	Limited to nasolabial folds	Focal subtle irregularity in 1 to 3 areas
1	Mild	Several (3–6) discrete small lentigines	Limited to nasolabial and early melolabial folds, mild lower eyelid laxity	Subtle irregularity
1.5	Mild	Multiple small lentigines	Localized nasolabial and melolabial folds, localized lower eyelid laxity	Mild irregularity in a few areas
2	Moderate	Multiple small and few large lentigines	Localized, prominent melolabial and nasolabial folds, diffuse and superficial lower eyelid laxity	Rough in a few localized areas
2.5	Moderate	Many (10–20) small and large lentigines	Prominent nasolabial and melolabial folds, diffuse with superficial lower eyelid and cheek laxity	Rough in several localized areas
3	Advanced	Numerous (>20) or multiple large lentigines	Prominent nasolabial and melolabial folds, prominent lower eyelid and cheek laxity	Rough in multiple localized areas
3.5	Advanced	Numerous (>20) lentigines with little uninvolved skin	Deep nasolabial and melolabial folds, prominent jowls, lower eyelid and cheek laxity	Mostly rough, little uninvolved skin
4	Severe	Numerous (>20) lentigines, extensive, no uninvolved skin	Marked nasolabial and melolabial folds, jowls, lower eyelid and cheek laxity	Rough throughout the face

Adapted from Alexiades-Armenakas M. J Drugs Dermatol 2006 Sep;5(8):808-9.

with make-up (lasting 5–7 days) minor crusting (lasting 24–72 hours), and bronzing of the skin (occurring at post-treatment day 3–4 and resolving by day 6–7).

During treatment, patients reported minimal pain, which was alleviated with the use of the topical and cold air anesthesia. There was no incidence of adverse events of scarring, prolonged erythema (lasting more than 7 days), postinflammatory hyper- or hypopigmentation, or infection in the 108 treatment sessions given during this study.

TABLE 2. Patient Demographic Information

Patient Demographics	*Value*
Age, mean	58.5
Female, n (%)	39 (86.7)
Male, n (%)	6 (13.3)
Fitzpatrick skin type, n (%)	
I	12 (26.7)
II	27 (60.0)
III	6 (13.3)
Number of treatments, mean	2.4

Blinded physicians assessed cosmetic outcome of improvement in photoaging on photographic analysis of the results of the 6-month post-treatment visit. Evaluating physicians were not aware of which treatment was before and after treatment.

From before treatment to 6 months after treatment, the mean score decreased from 3.3 to 1.7 for skin texture (48.5% mean improvement, 95% CI = 44.6–52.4%), from 3.0 to 1.5 (50.3% mean improvement, 95% CI = 46.1–54.5%) for skin laxity, from 3.2 to 1.5 (53.9% mean improvement,

TABLE 3. Improvement in Photoaging

Photoaging Scores	*Skin Texture*	*Skin Laxity*	*Dyschromia*	*Overall Cosmetic Outcome*
Before treatment	3.32	3.06	3.22	3.27
After treatment	1.66	1.48	1.47	1.52
Mean improvement, %	48.5	50.3	53.9	52.4
(95% confidence interval)	(44.6–52.4)	(46.1–54.5)	(49.5–58.5)	(47.9–56.9)
p-value: pre vs post-treatment score	$<.05$	$<.05$	$<.05$	$<.05$

95% CI = 49.5–58.5%) for dyschromia, and from 3.6 to 1.2 (52.4% mean improvement, 95% CI = 47.9–56.9%) for overall cosmetic outcome (all $p < .05$) (Table 3).

Clinical pictures of patients demonstrating improvement in photoaging are seen in Figures 1A and B, 2A and B, and 3A and B.

Discussion and Review of the Literature

This prospective study demonstrated that significant improvement in photoaging of the face can be achieved using an AFP device after a series of two to three treatments. The efficacy for skin laxity and skin pigmentation abnormalities seen with AFP in this study was significantly greater that that seen with the previous generation of nonablative lasers and NAFP devices,[17,18,30] with a similar rapid recovery and benign side-effect profile.

Before the advent of fractionated technology, the primary laser modality used for facial resurfacing was ablative laser devices (CO_2 and Er:YAG), which were associated with significant side effects of prolonged swelling, erythema, crusting, and hyperpigmentation, with potential long-term risks of permanent dyspigmentation and scarring and other textural abnormalities.[1–16] The pixilated pattern of wounding in FP, in which nonablated tissue surrounds columns of thermal damage, promotes faster re-epithelialization and greater tissue



Figure 1. (A) Before (left) and (B) after (right) two treatments of the face in a 74-year-old Caucasian man using ablative fractional photothermolysis (SmartXide DOT, DEKA, Calenzano, Italy) at settings of 30 W, 1,500 μs, and 500 μm. Degree of improvement: 67% in skin texture, 50% in laxity, 57% in dyschromia.



Figure 2. (A) Before (left) and (B) after (right) two treatments of the face in a 62-year-old Caucasian woman using ablative fractional photothermolysis (SmartXide DOT, DEKA, Calenzano, Italy) at settings of 30 W, 1,000 μs, and 500 μm. Degree of improvement: 50% in skin texture, 33% in laxity, 57% in dyschromia.

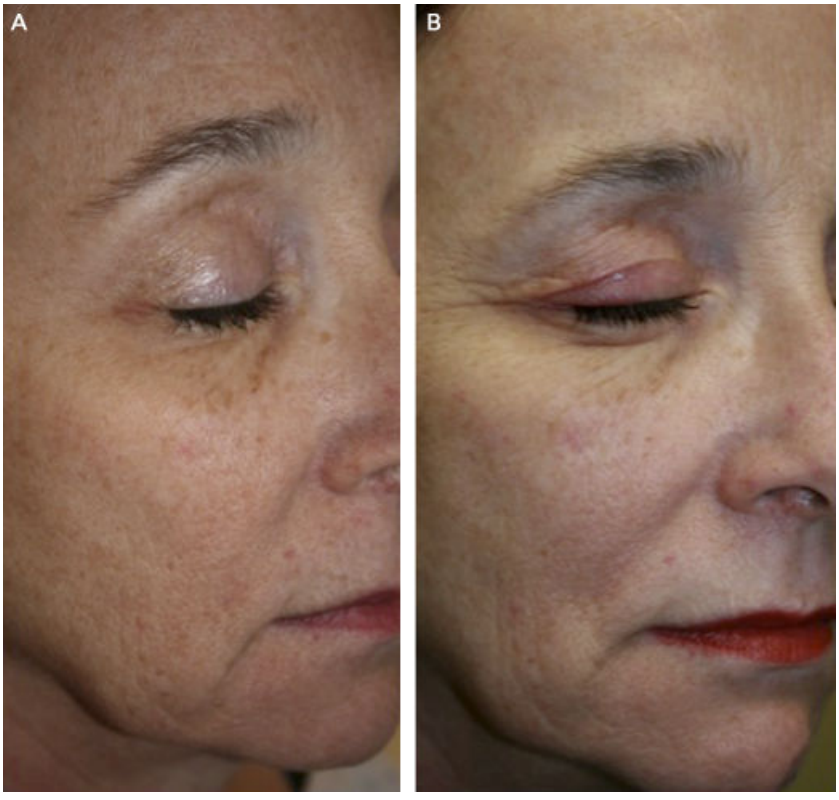

Figure 3. (A) Before (left) and (B) after (right) two treatments of the face in a 62-year-old Caucasian woman using an ablative fractional carbon dioxide laser (SmartXide DOT, DEKA, Calenzano, Italy) at settings of 30 W, 1,000 μs, and 500 μm. Degree of improvement: 33% in skin texture, 25% in laxity, 67% in dyschromia.

contraction and tightening.[17,18] As a result of the fractionated nature of tissue ablation, recovery time after treatment is minimized, and there is minimal to no risk of long-term postinflammatory change or scarring.[17,18]

Review of the recent literature demonstrates significant advantages of FP in terms of shorter recovery times and better side-effect profiles than with traditional ablative laser resurfacing devices (CO_2 and Er:YAG).[17–30] Although traditional ablative laser resurfacing was able to achieve results for skin tightening, the side effects of several months of erythema and swelling and long-term risks of prolonged dyspigmentation and potential scarring significantly limited the application of this technology.[11–16] One possible explanation for the greater degree of tightening observed with FP is the greater depth of dermal penetration that could not be achieved safely using traditional ablative devices.[19,20,26,27]

The rapid recovery times seen with fractionated CO_2 lasers marks a significant improvement over traditional CO_2 and Er:YAG laser resurfacing. It is postulated that the differences in healing time between traditional ablative resurfacing and fractional resurfacing result from differences in mechanisms of wound healing.[31] Traditional ablative laser wounds heal by migration of stem cells from hair follicles.[31] In contrast, with fractional ablative resurfacing, it is hypothesized that re-epithelialization occurs more rapidly because recovery occurs because of migration of neighboring cutaneous stem cells.[31] Additional histologic and molecular studies need to be performed to better characterize and understanding the healing mechanisms involved.

The mechanism of improvement in skin texture and tightening with AFP is not precisely known. It has been observed that, as tissue is ablated, there is an immediate bimodal collagen contraction and a second effect at 3 to 6 months afterward from persistent collagen remodeling.[31] This secondary effect of collagen contraction was correlated with the clinical results in our study, with the improvements in skin texture and laxity observed 6 months after treatment being significantly greater than those observed 8 weeks after treatment. On analysis of patient satisfaction with treatment, the majority of patients reported continued improvements in skin texture and laxity 6 months after treatment.

There are a number of fractionated CO_2 devices currently on the market with adjustable fluences and pulse durations, which allow targeting of the amount and depth of dermal heating delivered (Table 4). A number of recent studies have evaluated changes in photoaging with these devices, and clinical and histologic data have confirmed the exciting promise of these devices in achieving significantly greater improvements in skin texture and laxity than with the previous generation of NAFP devices.[24–31]

In 2009, Rahman and colleagues[24] reported a high degree of safety and efficacy in the treatment of photoaging using an AFP device in the FDA studies leading to approval of the device (Fraxel Repair, Reliant Technologies, Mountain View, CA). Patients were treated on the face and neck with settings of 10 to 40 mJ/MTZ and densities of 400 to 1,000 MTZ/cm^2). Average improvement in indices of skin texture and tightening (on a quartile scale) were 2.30 for rhytides, 2.42 for texture, and 1.65 for laxity.[24] A follow-up to this study was reported of the long-term outcomes of 10 subjects previously treated using fractional CO_2 resurfacing.[25] Patients returned for long-term follow-up visits at 1 and 2 years. Subjects maintained 74% of their overall improvement at their long-term visits compared with 3-month follow-up visits. Although clinical improvement was maintained over the long term, the results were not as remarkable as those seen at the 3-month visits. The authors speculated that persistent inflammatory changes may have enhanced results seen at 3 months, as evidenced by heat shock protein 47 activity and ongoing collagen remodeling seen in previous histologic studies. Although fractional CO_2 laser resurfacing has long-term efficacy and persistence of

TABLE 4. Fractional Ablative Laser Device Specifications

Manufacturer	*Wavelength*	*Pulse Duration*	*Delivery Method*	*Beam Spot Size*	*Scanner Area*	*Depth*
Alma Pixel XL Harmony	2,940-nm Er:YAG	1, 1.5, or 2 ms	Scanned	250 μm	11 × 11 mm	300 μm
Deka SmartXide DOT	10,600-nm CO_2	200 μs-2.0 ms	Scanned	350 μm	15 × 15 mm	200-1,500 μm
Ellipse Juvia	10,600-nm CO_2	2.0–7.0 ms	Scanned	500 μm	7 × 7/9 × 11 MTZ/cm^2	400 μm
Lasering USA Mixto SX	10,600-nm CO_2	2.5–16 ms	Scanned (four quadrant)	300/180 μm	20 × 20 mm	Ablation: 200-μm thermal damage: additional 300 μm
Lumenis	10,600-nm CO_2	< 1 ms	Scanned	1,300/120 μm	9 × 9/10 × 10 mm	10–300 μm (1,300-μm spot), 150–1,600 μm (120 μm), up to 3,200 μm with pulse stack
Lutronic	10,600-nm CO_2	Changes automatically with energy setting	Stamping dynamic	1,000/300/120 μm	14 × 14 mm	2,500 μm
Palomar Lux 2940	2,940-nm Er:YAG	0.2–5.0 ms	Stamping	100 μm	10 × 10/6 × 6 mm	200 μm
Reliant Re:pair	10,600-nm CO_2	0.15–3 ms	IOTS (paintbrush) continuous motion	< 140 μm	Not available	1,600 μm
Sciton Profractional	2,940-nm Er:YAG	Changes automatically with energy setting	Scanned	430/250 μm	20 × 20 mm	1,500 μm

YAG = yttrium aluminum garnet; CO_2 = carbon dioxide.

improvement of acne scarring and photodamage, additional treatments may be necessary to maintain or enhance long-term results.

Berlin and colleagues[26] performed a study in 10 subjects with one treatment using an AFP device (UltraPulse Encore, Lumenis Inc., Santa Clara, CA). The authors evaluated clinical change in photoaging and histologic and ultrastructural change in collagen deposition using light and electron microscopy.[26] Blinded investigator assessment of skin textural alterations and rhytid reduction revealed a mean improvement of 1.8 (on a 5-point scale) at 4 weeks and 1.6 at 24 weeks after treatment. Post-treatment biopsies documented greater fibrosis in the papillary dermis.[26] Additionally, electron microscopy revealed a decrease in the average diameter of the collagen fibrils, consistent with greater deposition of collagen type III, suggesting new collagen deposition induced by fractionated laser resurfacing.[26]

A recent study[27] demonstrated significant improvement in neck skin tightening using the Smartxide DOT (DEKA, Calenzano, Italy); after a series of one or two treatments with AFP, 63% improvement in skin texture, 57% improvement in skin tightening, and 51.4% improvement in skin rhytides were observed. This degree of improvement in skin tightening of the neck has previously been reported only with ablative CO_2 laser resurfacing.[27]

Karsai and colleagues[28] performed a randomized controlled double-blind split-face study to compare the effects of a single treatment with ablative fractional CO_2 and Er:YAG lasers for rhytides in the periorbital region. The evaluation included the profilometric measurement of wrinkle depth, Fitzpatrick wrinkle score, and the assessment of side effects and patient satisfaction. Both modalities showed a roughly equivalent effect on wrinkle depth and Fitzpatrick score of periorbital rhytides, with both being reduced approximately 20% and 10%, with no appreciable difference between lasers. Side effects and discomfort were slightly greater after Er:YAG treatment in the first few days, but in the later course, there were more complaints after CO_2 laser treatment. Patient satisfaction was fair, and the majority of patients would have undergone the treatment again, without a clear preference for either method. In this study, a single ablative fractional treatment session had an appreciable yet limited effect on periorbital rhytides, with multiple sessions probably required for more-extensive improvement.

A recent report by Goldberg and colleagues[29] evaluated the treatment of perioral rhytides using a fractionated ablative erbium-doped yttrium scandium gallium garnet (Er:YSGG) laser (2,790 nm). This device has a water absorption coefficient between that of CO_2 and Er:YAG lasers. All subjects underwent a two-pass full-face treatment for rhytides at 160 mJ and 8% density. For perioral rhytides, subjects were treated using a 160-mJ first pass and a second and third pass of 200 mJ at 12% density. Based on the Fitzpatrick Scoring System for wrinkles at baseline and final follow-up, a statistically significant mean reduction of 1.25 ± 0.71 was observed in overall wrinkle score (from 5.88 to 4.63, $p = .002$) and perioral wrinkle score (from 5.63 to 4.38, $p = .002$). No incidence of scarring, postinflammatory pigmentary changes, or infections was observed. The authors reported that the Er:YSGG laser was safe and effective for photodamage and perioral rhytides.

The device used in the current study, the Smartxide DOT, has a variable pulse duration (200–2.0 ms) with a 350-μm beam spot size, a scanner area of 15×15 mm, and a penetration depth of 200 to 1,500 μm. In contrast, the Lumenis Deep FX and the Reliant Re:pair have similar ranges for pulse duration and scanner area but have spot sizes of 120 to 140 μm, with depths of 150 to 1,600 μm and up to 3,200 μm with pulse stacking. In a recent study, the DEKA device outperformed the Lumenis and the Reliant AFP devices in improvement in texture, rhytides, and overall clinical improvement.[30] The DEKA device achieved significant improvements in skin texture (3.0 on a quartile scale, 0–4), rhytides (2.6), and overall improvement (2.6).[30] In contrast,

the Reliant device achieved improvement in skin texture of 2.0, of rhytides of 2.1, and overall of 2.1.[30] Similarly, the Lumenis device achieved improvement in skin texture of 2.1, of rhytids of 2.0, and overall of 2.1 ($p < .05$).[30] With the other parameters (pulse duration, scanner area, and penetration depth) being largely equivalent between these three devices, the larger spot size of the DEKA device may partially account for the greater degree of improvement seen, particularly in the textural signs of photoaging seen with this device.[30]

A recent study[31] reported a comparison of four AFP devices in the treatment of the pigmentary and textural components of photoaging, the Fraxel re:pair (Solta Medical, Inc., Hayward CA), Active and Deep FX (Lumenis, Santa Clara, CA), Quadralase (Candela Corporation, Wayland, MA), and Pearl Fractional (Cutera, Brisbane, CA). Twelve patients aged 30 to 65 with moderate to severe sun damage and Fitzpatrick skin types I to IV were treated in the four quadrants of the face. Blinded evaluators assessed patients 1, 3, and 6 months after treatment to evaluate changes in skin texture, lentigines, pore size, and rhytides. One- and 3-month follow-up data showed improvement in photoaging in all patients studied in all quadrants. No differences have been observed between the four devices studied, but one of the significant challenges with this study was in setting equivalent parameters across the four devices studied. In future studies, extensive preoperative trials will be needed to establish comparative settings in studies comparing two or more devices.

Another novel fractional technology, fractional radiofrequency (FRF), has recently been reported to be effective in the treatment of photoaging. Armenakas and colleagues reported on the efficacy of a minimally invasive FRF device, MiratoneTM, in a prospective open-label multicenter clinical trial for treatment of facial rhytides and laxity.[32] One hundred subjects with mild to severe facial rhytides and laxity were enrolled at seven sites. Patients received FRF treatment of the lower face. Mean improvements in rhytides and laxity after a single treatment were 24% and 22%, respectively. Histologic analysis demonstrated neocollagenesis and neoelastogenesis in treated skin. Randomized comparative analysis demonstrated that a single FRF treatment yielded 33% of the mean surgical facelift improvement, but two patients experienced a total of seven incidences of epidermal injury associated with incomplete electrode insertion (< 0.01% of insertions) leading to punctate atrophy (1-mm diameter, < 12-mm depth). Additional evaluation of this technology, given its variable safety and efficacy profile, is needed to establish the efficacy of fractional radiofrequency.

It has been reported with FP in clinical–histologic correlation experiments that a greater depth of injury maximizes texture improvement, whereas a higher density of more-superficial injuries maximizes improvement in pigmentation.[17,18,26,35–37] Part of the rationale for the significant degree of improvement in skin texture and laxity obtained in this series is the long pulse duration applied (1,000–1,500 μs).[37] Clinical and histologic correlation studies by our group have identified greater improvement in tissue tightening associated with the greater depth of penetration of this AFP device at longer dwell times.[37] Specifically, at a dwell time of 1,000 to 1,500 μs, the MTZ of ablation extends to the depth of the deep reticular dermis.[37] Thus, the pattern of deep ablation into the reticular dermis and resultant stimulation of collagen contraction and synthesis probably accounts for its greater efficacy in tissue tightening and skin texture.

Conclusions

AFP has become the most promising new option for safe, nonsurgical improvement in rhytides, photodamage, and scarring. With proper technique, results approaching those seen with traditional CO_2 laser resurfacing can be achieved with a low risk of scarring and hypopigmentation. The short recovery periods required after AFP treatments, combined with its safety and an expanding array

of applications, are likely to ensure AFP's place in the cosmetic therapeutic arsenal for years to come.

References

1. Alster TS, Garg S. Treatment of facial rhytides with a high-energy pulsed carbon dioxide laser. Plast Reconstr Surg 1996;98:791–4.
2. Ward DP, Baker SR. Long-term results of carbon dioxide laser resurfacing of the face. Arch Facial Plast Surg 2008;10:238–43.
3. Waldorf HA, Kauvar AN, Geronemus RG. Skin resurfacing of fine to deep rhytides using a char-free carbon dioxide laser in 47 patients. Dermatol Surg 1995;21:940–6.
4. Fitzpatrick RE, Goldman MP, Satur NM, et al. Pulsed carbon dioxide laser resurfacing of photo-aged facial skin. Arch Dermatol 1996;132:395–402.
5. Manuskiatti W, Fitzpatrick RE, Goldman MP. Long-term effectiveness and side effects of carbon dioxide laser resurfacing for photoaged facial skin. J Am Acad Dermatol 1999;40:401–11.
6. Alster TS, West TB. Resurfacing of atrophic facial acne scars with a high-energy, pulsed carbon dioxide laser. Dermatol Surg 1996;22:151–4.
7. Walia S, Alster TS. Prolonged clinical and histologic effects from CO_2 laser resurfacing of atrophic acne scars. Dermatol Surg 1999; 25:926–30.
8. Prado A, Andrades P, Danilla S, et al. Full-face carbon dioxide laser resurfacing: a 10-year follow-up descriptive study. Plast Reconstr Surg 2008;121:983–93.
9. Dijkema SJ, van der Lei B. Long-term results of upper lips treated for rhytides with carbon dioxide laser. Plast Reconstr Surg 2005;115:1731–5.
10. Alster TS. Cutaneous resurfacing with CO_2 and erbium: YAG lasers: preoperative, intraoperative, and postoperative considerations. Plast Reconstr Surg 1999;103:619–32; discussion 633–4.
11. Ward PD, Baker SR. Long-term results of carbon dioxide laser resurfacing of the face. Arch Facial Plast Surg 2008;10:238–43; discussion 244–5.
12. Alexiades-Armenakas MR, Dover JS, Arndt KA. The spectrum of laser skin resurfacing: nonablative, fractional, and ablative laser resurfacing. J Am Acad Dermatol 2008;58:719–37.
13. Helm TN, Shatkin S Jr. Alabaster skin after CO_2 laser resurfacing: evidence for suppressed melanogenesis rather than just melanocyte destruction. Cutis 2006;77:15–7.
14. Weinstein C. Carbon dioxide laser resurfacing. Long-term follow-up in 2,123 patients. Clin Plast Surg 1998;25:109–30. Review.
15. Nanni CA, Alster TS. Complications of carbon dioxide laser resurfacing. An evaluation of 500 patients. Dermatol Surg 1998; 24:315–20.
16. Bernstein LJ, Kauvar AN, Grossman MC, Geronemus RG. The short- and long-term side effects of carbon dioxide laser resurfacing. Dermatol Surg 1997;23:519–25.
17. Manstein D, Herron GS, Sink RK, Tanner H, et al. Fractional photothermolysis: a new concept for cutaneous remodeling using microscopic patterns of thermal injury. Lasers Surg Med 2004;34:426–38.
18. Laubach HJ, Tannous Z, Anderson RR, Manstein D. Skin responses to fractional photothermolysis. Lasers Surg Med 2006;38:142–9.
19. Taub AF. Fractionated delivery systems for difficult to treat clinical applications: acne scarring, melasma, atrophic scarring, striae distensae, and deep rhytides. J Drugs Dermatol 2007;6:1120–8.
20. Hantash BM, Bedi VP, Kapadia B, Rahman Z, et al. In vivo histological evaluation of a novel ablative fractional resurfacing device. Lasers Surg Med 2007;39:96–107.
21. Weiss R, Weiss M, Beasley K. Prospective split-face trial of a fixed spacing array computed scanned fractional CO2 laser versus hand scanned 1,550 nm fractional for rhytids. Abstract presented at American Society for Laser Medicine and Surgery Conference, April 2008, Kissimee, FL.
22. Lomeo G, Cassuto D, Scrimali L, Sirago P.. Er:YAG versus CO_2 ablative fractional resurfacing: a split face study. Abstract presented at American Society for Laser Medicine and Surgery Conference, April 2008, Kissimee, FL.
23. Ross V, Swann M, Barnette D. Use of a micro-fractional 2,940 nm laser in the treatment of wrinkles and dyspigmentation. Abstract presented at American Society for Laser Medicine and Surgery Conference, April 2008, Kissimee, FL.
24. Rahman Z, MacFalls H, Jiang K, Chan KF, et al. Fractional deep dermal ablation induces tissue tightening. Lasers Surg Med 2009; 41:78–86.
25. Ortiz AE, Tremaine AM, Zachary CB. Long-term efficacy of a fractional resurfacing device. Lasers Surg Med 2010;42:168–70.
26. Berlin AL, Hussain M, Phelps R, Goldberg DJ. A prospective study of fractional scanned nonsequential carbon dioxide laser resurfacing: a clinical and histopathologic evaluation. Dermatol Surg 2009;35:222–8.
27. Tierney EP, Hanke CW. Neck tightening with an ablative fractionated CO_2 laser: case series and review of the literature. J Drugs Dermatol 2009;8:723–31.
28. Karsai S, Czarnecka A, Jünger M, Raulin C. Ablative fractional lasers (CO(2) and Er:YAG): a randomized controlled double-blind split-face trial of the treatment of peri-orbital rhytides. Lasers Surg Med 2010;42:160–7.
29. Goldberg D, Ciocon D, Engelman D, Hussain M. Treatment of perioral rhytides with a new fractional ablative ER:YSGG (2,790 nm) laser. Presented at the American Society for Laser Medicine and Surgery Conference, April 2010, Phoenix AZ.
30. Waibel J, Beer K, Narurkar V, Alster T. Preliminary observations on fractional ablative resurfacing devices: clinical impressions. J Drugs Dermatol 2009;8:481–5.
31. Abbasi N, LaTowsky B, Arndt K, Dover J, et al. Comparison of four ablative fractional devices in the treatment of photoaging. Presented at the American Society for Laser Medicine and Surgery Conference, April 2010, Phoenix AZ.
32. Alexiades-Armenakas M, Willey A, Kilmer S, Goldberg DJ, et al. Prospective open-label multicenter clinical trial evaluating the efficacy of fractional radiofrequency for treatment of facial rhytids and laxity. Presented at the American Society for Laser Medicine and Surgery Conference, April 2010, Phoenix AZ.

33. Tierney EP, Hanke CW, Petersen JP, Bartley T, et al. Clinical and echographic analysis of ablative fractionated carbon dioxide laser in the treatment of photodamaged facial skin. Dermatol Surg 2010;36:2009–21.

34. Tierney EP, Hanke CW. Treatment of poikiloderma of Civatte with ablative fractional laser resurfacing: prospective study and review of the literature. J Drugs Dermatol 2009;8:527–34.

35. Tierney EP, Kouba DJ, Hanke CW. Review of fractional photothermolysis: treatment indications and efficacy. Dermatol Surg 2009;35:1445–61.

36. Walgrave S, Zelickson B, Childs J, Altshuler G, et al. Pilot investigation of the correlation between histological and clinical effects of infrared fractional resurfacing lasers. Dermatol Surg 2008;34:1443–53.

37. Tierney EP, Hanke CW. Histologic analysis of ablative fractionated CO2 laser in the treatment of photodamaged facial skin. J Am Acad Dermatol in press.

Address correspondence and reprint requests to: C. William Hanke, MD, MPH, 13400 N. Meridian Street, Suite 290, Carmel, IN 46032, or e-mail: cmwhanke@thelassi.com