

CASE REPORT

Periocular syringomas – Successful treatment with fractional CO₂ laser

Alberto Goldman¹, Uwe Wollina^{2*}¹ Clinica Goldman, Porto Alegre/ RS, Brazil² Department of Dermatology and Allergology, Academic Teaching Hospital Dresden-Friedrichstadt, Dresden, Germany

Abstract: Syringoma is a benign tumor of eccrine origin which arises from eccrine ducts. Syringomas are most commonly found on the eyelids in middle-aged women. Traditional treatments include surgical excision, curettage, peelings, dermabrasion and laser. We report on the successful use of fractional laser on periocular syringomas. A 53-year-old female patient with multiple periorbital syringomas underwent three sessions of fractional carbon dioxide (CO₂) laser. Settings of 20 watts of power, 600 μm of spacing, 800 μs of dwell, time stack 2 (Smartxide DOT, DEKA, Florence, Italy) were used. The sessions were performed monthly. Significant improvement of the esthetic appearance was observed after three sessions. There was a decrease of visible syringomas associated with an evident improvement of the skin texture, skin quality and flaccidity. No side effects were observed. We suggested continuing the treatment but the patient was satisfied with the current aspect and result. In conclusion, fractional CO₂ laser represents an effective treatment option for the treatment of periorbital syringomas.

Keywords: Syringoma; treatment; esthetics; fractional CO₂ laser

Citation: Goldman A and Wollina U. Periocular syringomas – Successful treatment with fractional CO₂ laser. J Surg Dermatol 2017; 2(T1): <http://dx.doi.org/10.18282/jsd.v2.it1.145>.

*Correspondence to: Uwe Wollina, Department of Dermatology and Allergology, Academic Teaching Hospital Dresden-Friedrichstadt, Friedrichstrasse 41, 01067 Dresden, Germany, wollina-uw@khdf.de.

Received: 12th March 2017; **Accepted:** 29th March 2017; **Published Online:** 7th April 2017

Introduction

Syringoma is a benign adnexal tumor with eccrine differentiation that affects 0.6% of the general population with an age-peak in the second and third decade of life. Different clinical subtypes have been described, e.g. localized or generalized, sporadic, familiar and associated with Down's syndrome. Eruptive syringoma is a rare generalized subtype that has occasionally been reported as a possible paraneoplastic disease. The most common type, however, is the sporadic localized one. The majority of these tumors arise in the head and neck region, and genital manifestation is rare^[1-4]. In contrast to periocular syringomas, which are mostly asymptomatic, genital tumors may be associated with pruritus and pain^[5].

Histologically, syringomas are symmetrical, well-circ-

mscribed cysts and cords or strands localized in the upper dermis, without any connection to the epidermis. The proliferations have been coined comma- or tadpole-shaped, lined by single or double layers of cuboidal epithelial cells. Immunohistological investigations suggest an eccrine duct origin^[6]. The solid strands seem to originate from the outer cells of the lower epidermal duct or the transitional portion between the intraepidermal duct and dermal duct in the normal eccrine gland^[7].

Case report

A 53-year-old female patient presented with multiple 1 to 3 mm large, skin-colored or slightly yellowish, periocular syringomas (**Figure 1A**). The patient provided written consent to publish the figures in this manuscript.

For at least 10 years she experienced these lesions, which slowly progressed. Before treatment, the diagnosis had been confirmed elsewhere with an ablative CO₂ laser. However, the outcome after 13 sessions was poor. Therefore, this patient was referred to another type of therapy.

Two years ago, she had an upper and lower blepharoplasty. There was an improvement in the skin and fat bags, but no change in the skin quality or in the syringomas. Ten years ago, she had a cardiac valve surgery. Therefore, she took 100 mg of acetylsalicylic acid per day. There was no family history of syringomas.

The patient was treated with three sessions of fractional CO₂ laser using the following parameters: 20 watts of power, 600 μm of spacing, 800 μs of dwell, time stack 2 (Smartxide DOT, DEKA, Florence, Italy). The sessions were performed monthly. Topical prilocaine-lidocaine ointment was used for anesthesia. In the beginning of the session, single shots were placed on the tiny tumors followed by complete treatment of the periorbital area using the scanner. Significant improvement of the esthetic appearance was observed after three sessions. There was a decrease of visible syringomas associated with an evident improvement of the skin texture, skin quality and flaccidity (**Figure 1B**). No side effects were observed. We suggested that she continue with the treatment, but the patient was satisfied with the outcome.

There was no relapse during the next 12 months after the last laser session.

Discussion

Periocular syringomas are often asymptomatic but may compromise the facial esthetic appearance. Therefore, patients ask for safe and effective treatment. Ablative non-fractional lasers have been used in the past with

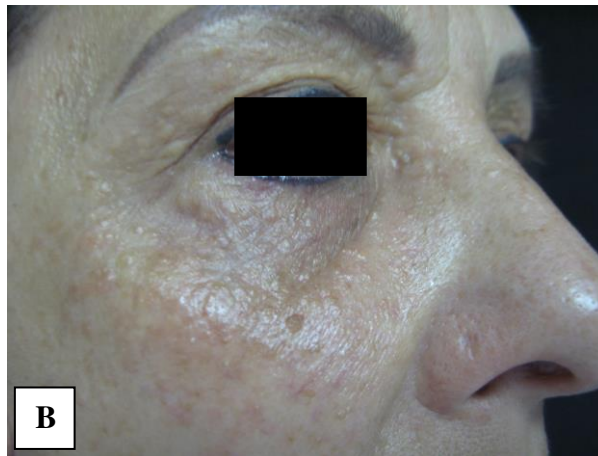
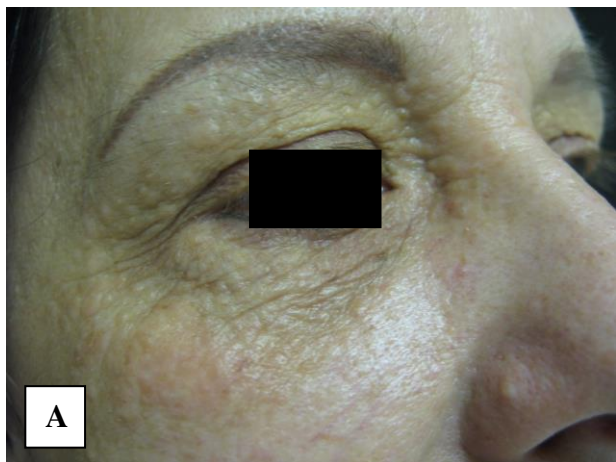


Figure 1. A 53-year-old female patient with multiple recalcitrant periocular syringomas on photoaged skin. (A) Before treatment with fractional CO₂ laser. (B) Outcome after three sessions of fractional CO₂ laser with marked reduction of syringoma count and significant improvement of periocular esthetics

mixed results (**Table 1**). Wollina previously treated 24 patients with eyelid syringomas with an erbium-doped yttrium-aluminium-garnet (Er:YAG) laser. Between one and three sessions were necessary to remove more than 80% of these tiny eccrine tumors. However, relapse occurring during the hot summer has occasionally been noted. There was no comparable rejuvenating effect as seen in the present case^[8].

Fractional CO₂ laser combines fractional photothermolysis and the formation of coagulation zones with an ablative 10,600-nm wavelength, which allows for the effective treatment of photoaging, rhytides, and scars. Compared to classical CO₂ laser, recovery periods are significantly shorter and the risk of scar formation by the treatment is minimized^[9]. The depth of tissue ablation is dependent on the power, fluence, spot size and density used. The dermal remodeling involves the expression of heat-shock proteins^[10,11]. Several aspects of aging skin can be improved such as dyschromia, skin texture, and fine lines^[12].

For the present patient, who had been treated with ablative CO₂ laser with only slight changes, we decided to switch to the advanced technology of fractional CO₂ laser. The treatment was very successful, not only in diminishing the syringoma count, but in the rejuvenation of the whole periocular area. Further studies are needed for verification.

Conclusion

Syringomas are eccrine benign tumors of skin occurring

Table 1. Treatment outcome in syringomas in studies with more than 20 patients

Treatment	Patients	Outcome	Reference
Erb:YAG laser	24	>80% improvement after 1 to 3 sessions	Wollina, 2016 ^[8]
Erb:YAG laser	49	>75% improvement in 88% after 4 sessions	Kitano, 2016 ^[13]
CO ₂ laser + BoTN*	48	87.5% of >60% improvement (CO ₂ + BoTN) 70.5% (CO ₂ alone)	Seo <i>et al.</i> , 2016 ^[14]
CO ₂ laser	29	>75% improvement in 24.1% after 2 sessions	Lee <i>et al.</i> , 2015 ^[15]
Fractional CO ₂ laser	35	>75% improvement in 8.6% after 2 sessions	Cho <i>et al.</i> , 2011 ^[16]

*BoTN – Botulinum toxin

most frequently in the head and neck area. As suggested by our own experience, fractional CO₂ laser may be an effective and safe tool to improve facial appearance for the treatment of multiple periocular syringomas that poorly respond to ablative CO₂ laser. We recommend a combination of pinhole shots for syringomas, with scanner-assisted laser treatment of the whole affected area to optimize outcome.

Author contributions

A Goldman and U Wollina prepared the manuscript and evaluated the outcome after treatment. First consultation and laser treatment were done by A Goldman. Both authors have read and approved the final version of the manuscript.

Conflict of interest

The authors declare no potential conflict of interest with respect to the research, authorship, and/or publication of this article.

References

- Lee JH, Chang JY, Lee KH. Syringoma: A clinicopathologic and immunohistologic study and results of treatment. *Yonsei Med J* 2007; 48(1): 35–40. doi: 10.3349/ymj.2007.48.1.35.
- Ghanadan A, Khosravi M. Cutaneous syringoma: A clinicopathologic study of 34 new cases and review of the literature. *Indian J Dermatol* 2013; 58(4): 326. doi: 10.4103/0019-5154.113956.
- Turan E, Yurt N, Yeşilova Y, Tanrikulu O. A rare association in Down syndrome: Milialike idiopathic calcinosis cutis and palpebral syringoma. *Cutis* 2016; 98(6): E22–E23.
- Incel Uysal P, Yalcin B, Ozhamam E, Bozdogan O. Co-existence of adult onset eruptive syringoma and bilateral renal cell carcinoma: A case report. *Am J Dermatopathol* 2017; 39(1): 56–58. doi: 10.1097/DAD.0000000000000592.
- Kavala M, Can B, Zindanci I, Kocatürk E, Türkoğlu Z, *et al.* Vulvar pruritus caused by syringoma of the vulva. *Int J Dermatol* 2008; 47(8): 831–832. doi: 10.1111/j.1365-4632.2008.03664.x.
- Wollina U, Schaarschmidt H, Rülke D. Sweat gland tumors of skin—Immunohistochemistry with common antibodies in the paraffin section. *Int J Oncol* 1992; 1(4): 395–402. doi: 10.3892/ijo.1.4.395.
- Kim BC, Park EJ, Kwon IH, Cho HJ, Park HR, *et al.* An immunohistochemical study of the origin of the solid strand in syringoma, using carcinoembryonic antigen, epithelial membrane antigen, and cytokeratin 5. *Int J Dermatol* 2012; 51(7): 817–822. doi: 10.1111/j.1365-4632.2011.05069.x.
- Wollina U. Erbium-YAG laser therapy—Analysis of more than 1,200 treatments. *J Glob Dermatol* 2016; 3(2): 268–272. doi: 10.15761/GOD.1000171.
- Hunzeker CM, Weiss ET, Geronemus RG. Fractionated CO₂ laser resurfacing: Our experience with more than 2000 treatments. *Aesthet Surg J* 2009; 29(4): 317–322. doi: 10.1016/j.asj.2009.05.004.
- Grunewald S, Bodendorf M, Illes M, Kendler M, Simon JC, *et al.* *In vivo* wound healing and dermal matrix remodelling in response to fractional CO₂ laser intervention: Clinicopathological correlation in non-facial skin. *Int J Hyperthermia* 2011; 27(8): 811–818. doi: 10.3109/02656736.2011.595380.
- Skovbølling Haak C, Illes M, Paasch U, Hædersdal M. Histological evaluation of vertical laser channels from ablative fractional resurfacing: An *ex vivo* pig skin model. *Lasers Med Sci* 2011; 26(4): 465–471. doi: 10.1007/s10103-010-0829-2.
- Tierney EP, Hanke CW, Petersen J. Ablative fractionated

- CO₂ laser treatment of photoaging: A clinical and histologic study. *Dermatol Surg* 2012; 38(11): 1777–1789. doi: 10.1111/j.1524-4725.2012.02572.x.
13. Kitano Y. Erbium YAG laser treatment of periocular syringomas by using the multiple ovoid-shape ablation method. *J Cosmet Laser Ther* 2016; 18(5): 280–285. doi: 10.3109/14764172.2016.1157361.
 14. Seo HM, Choi JY, Min J, Kim WS. Carbon dioxide laser combined with botulinum toxin A for patients with periocular syringomas. *J Cosmet Laser Ther* 2016; 18(3): 149–153. doi: 10.3109/14764172.2015.1052517.
 15. Lee SJ, Goo B, Choi MJ, Oh SH, Chung WS, *et al.* Treatment of periocular syringoma by the pinhole method using a carbon dioxide laser in 29 Asian patients. *J Cosmet Laser Ther* 2015; 17(5): 273–276. doi: 10.3109/14764172.2015.1027224.
 16. Cho SB, Kim HJ, Noh S, Lee SJ, Kim YK, *et al.* Treatment of syringoma using an ablative 10,600-nm carbon dioxide fractional laser: A prospective analysis of 35 patients. *Dermatol Surg* 2011; 37(4): 433–438. doi: 10.1111/j.1524-4725.2011.01915.x.