

# Randomized, Controlled Trial of Fractional Carbon Dioxide Laser Resurfacing Followed by Ultrashort Incubation Aminolevulinic Acid Blue Light Photodynamic Therapy for Actinic Keratosis

MACRENE ALEXIADES, MD, PhD\*†

**BACKGROUND** Aminolevulinic acid (ALA) photodynamic therapy (PDT) is an established treatment option for actinic keratosis (AK), and recently fractional carbon dioxide (CO<sub>2</sub>) laser was shown to improve outcomes; but studies of short incubation photosensitizer are lacking.

**OBJECTIVE** Assess the efficacy of short incubation ALA followed by blue light PDT with and without previous fractional CO<sub>2</sub> treatment for the treatment of AK.

**METHODS** Randomized, paired split-design, controlled trial of fractional CO<sub>2</sub> followed by ultrashort 15-minute versus 30-minute incubation ALA and blue light PDT for the treatment of AK on the face.

**RESULTS** The complete clearance rates (CRs) at 8 weeks after ALA PDT with and without FxCO<sub>2</sub> at 30- and 15-minute ALA incubation times were 89.78% (+FxCO<sub>2</sub>) versus 71.20% CR (–FxCO<sub>2</sub>) at 30', and 86.38% (+FxCO<sub>2</sub>) versus 69.23% (–FxCO<sub>2</sub>) at 15' ALA incubation. All lesion improvements were statistically significant.

**CONCLUSION** This randomized, comparative paired group controlled clinical study demonstrates that ultrashort 15- and 30-minute incubation ALA PDTs are of limited efficacy for the treatment of AK. Pretreatment with fractional ablative resurfacing yields statistically significant greater AK clearance with ALA-PDT at ultrashort ALA incubations followed by blue light.

*DUSA provided the Levulan kerastick and DEKA Medical provided statistical analysis support for this research project; the remainder was self-funded. The author has received research funding in the past from both companies.*

The risk of progression of actinic keratosis (AK) to squamous cell carcinoma (SCC) is significant. Previous reports indicated a 10% progression per decade, and a recent study has shown a 0.60% AK to SCC progression at 1 year and 2.57% at 4 years, with 65% of primary SCCs arising in previously diagnosed AKs.<sup>1</sup> However, a recent systematic literature review reported that progression rates of AK to SCC ranged from 0% to 0.075% per lesion-year, with a risk of up to 0.53% per lesion in patients with previous history of nonmelanoma skin cancer.<sup>2</sup> AK lesion clearance rates (CRs) on face and scalp after 20% aminolevulinic acid (ALA) solution at 14- to 18-hour incubation and blue light at 10 mW/cm<sup>2</sup> for 1,000 seconds have been

reported at 88% at 8-week follow-up and 89% at 3-month follow-up.<sup>3,4</sup> The long-term CR after 2 treatments for AK on the face or scalp was 78% at 12-month follow-up.<sup>5</sup> The side effect profile at these long incubation times have included burning discomfort during treatment and postprocedure edema, erythema, and crusting. In addition, long incubation times have made ALA photodynamic therapy (PDT) time-consuming for the patient and clinician.

Research has been conducted to shorten ALA incubation times. A recent study of the kinetics of PpIX accumulation in AK after topical ALA application demonstrated that PpIX concentration was statistically higher than

\*Department of Dermatology, Yale University School of Medicine, New Haven, Connecticut; †Dermatology and Laser Surgery Center, New York, New York

© 2017 by the American Society for Dermatologic Surgery, Inc. Published by Wolters Kluwer Health, Inc. All rights reserved.  
ISSN: 1076-0512 • Dermatol Surg 2017;0:1–12 • DOI: 10.1097/DSS.0000000000001117

baseline in 92% of lesions by 1 hour and 100% of lesions by 2 hours, and that PpIX levels were also elevated in areas of normal-appearing nonlesional skin.<sup>6</sup> A therapeutic fluence (10 J/cm<sup>2</sup>) of blue light was applied to lesions 2 hours after ALA application, and 1 month after treatment, the vast majority of AKs resolved.<sup>6</sup> Data from other studies with similar short incubation times also appeared efficacious for AK treatment.<sup>7-9</sup> Reported AK CRs after 1 hour of ALA blue light for AK were 80% at 4-week follow-up<sup>7</sup>; 90% AK CR at 5-month follow-up<sup>8</sup>; and most recently, 68% AK CR at 12 weeks.<sup>9</sup> These studies suggest that ultrashort incubation times may also yield adequate efficacy of AK clearance.


Another factor impacting PDT CR is the degree of hyperkeratosis, where inferior treatment outcomes are thought to be due to limited penetration depth of the photosensitizer and a diminished PDT response to the deeper aspect of the AK. Options for increasing photosensitizer drug delivery have included occlusion of the skin, chemicals that disrupt the stratum corneum barrier, iontophoresis of charged drugs, ultrasound disruption of stratum corneum, microneedle puncture, curettage, tape stripping, and microdermabrasion techniques, which may increase the ALA/methyl aminolevulinate (MAL) bioavailability in the deep skin layers.<sup>10</sup> Recently, fractional ablative lasers have been applied with success to augment photosensitizer delivery and AK CR; however, the vast majority of these studies have been with MAL PDT.<sup>11-16</sup> Only 1 study examined pretreatment fractional CO<sub>2</sub> laser and 90-minute incubation ALA with red light.<sup>16</sup> With a dearth of previous data evaluating the impact of fractional ablative laser pretreatment on ALA blue light PDT, the goal of this study is to examine the effects of fractional CO<sub>2</sub> laser resurfacing (FxCO<sub>2</sub>) on ALA blue light PDT AK CR at ultrashort incubation times of 15' and 30'. In this randomized, blinded, paired-design, controlled clinical trial of FxCO<sub>2</sub>-assisted ultrashort incubation ALA PDT for the treatment of AK, increasing photosensitizer delivery serves to increase ALA-PDT efficacy and shorten ALA incubation times.

**Patients and Methods**

A comparative paired group design was used comparing ALA-PDT to FxCO<sub>2</sub>-ALA-PDT in a split-face compar-

ison and 2 treatment arms of 10 subjects each, comparing 15- and 30-minute ALA incubation (Figure 1). The 4 treatment arms were with fractional CO<sub>2</sub> (+Fx) and without fractional CO<sub>2</sub> (-Fx) at 30-minute (30') or 15-minutes (15') ALA incubation times (Figure 1). Verbal and written informed consent regarding the potential benefits and risks of the procedure was obtained from each subject. Subjects were informed that the treatment is part of a protocol and that the combination of topical 5-ALA solution with the blue light and fractional CO<sub>2</sub> laser resurfacing were each approved by the Food and Drug Administration (FDA), although it had approved both for use independently. Subjects were informed that application of ALA at short 15- and 30-minute incubations were off-label, as the labeled use is a 14- to 18-hour overnight incubation.

Each AK lesion was photographed, numbered, and mapped at baseline. Since each subject was required to have at least 4 AK lesions per side for enrollment, each split-side of face for each subject was randomly assigned to treatment with ALA-PDT or with FxCO<sub>2</sub>-ALA-PDT, using alternate randomization (allocation 1:1). AK lesions pretreated with FxCO<sub>2</sub> before ALA-PDT were categorized as the FxCO<sub>2</sub>-ALA-PDT group, and AK lesions treated with ALA-PDT alone defined as the control group (ALA-PDT group). The lesions were cleansed with saline-soaked gauze followed by acetone before treatment. For all groups, lidocaine/prilocaine (5%) cream (EMLA; Astra Pharmaceuticals, LP, Westborough, MA) was applied to the entire treatment area for 30 minutes. After the anesthetic cream was removed, FxCO<sub>2</sub> resurfacing was



**Figure 1.** Study design. A comparative paired group design was used comparing aminolevulinic acid (ALA)-photodynamic therapy (PDT) to FxCO<sub>2</sub>-ALA-PDT in a split-face comparison and 2 treatment arms of 10 subjects each, comparing 15- and 30-minute ALA incubation.

performed using a 10,600-nm CO<sub>2</sub> fractional laser (Smartxide DOT; DEKA Medical, DEKA M.E.L.A. S. r.l, Calenzano FI, Italy) at a 20 W, 300- $\mu$ m microbeam diameter, 550- $\mu$ m dot spacing and 700-ms dwell time at a single pass to the randomized side. These settings correspond to an approximate 300- $\mu$  penetration depth and a treated surface area of 27%. Immediately after FxCO<sub>2</sub> treatment, 20% ALA (Levulan; DUSA pharmaceuticals, Wilmington, MA) was applied to all lesions in 2 coats and on 5 mm of surrounding normal tissue. After incubation for 15 or 30 minutes depending on the treatment arm, the area was irradiated with blue light (Blu-U; DUSA pharmaceuticals) for 1,000 seconds (16 minutes 40 seconds). All patients wore protective goggles during illumination.

### Clinical Assessments

To evaluate the response to therapy, all patients were followed up at 4 and 8 weeks following 1 treatment. The investigator conducted all safety evaluations and investigator-assessed efficacy evaluations. A blinded evaluator determined the response to treatment using the efficacy evaluations detailed below at the 8-week follow-up interval.

### Efficacy

#### Primary Endpoints

The primary end point was the AK CR. The CR was evaluated by inspecting, photographing, and palpating each lesion (in accordance with the guidelines of Olsen and colleagues), and classified as either complete response (complete disappearance of the lesion), or noncomplete response (incomplete disappearance of the lesion). The CR was calculated as the percentage of lesions with complete response over baseline.

#### Secondary Endpoints

The secondary end point was the cosmetic outcome, which was assessed 8 weeks after treatment by patient and investigator, and graded as excellent (slight redness and significant pigmentation improvement), good (moderate redness and moderate pigmentation improvement), fair (slight-to-moderate scarring, atrophy, or induration and no pigmentation

improvement), or poor (extensive scarring, atrophy, or induration and pigmentation worsening).

### Photography

Digital photography Nikon SLR 300S in identical setting and lighting baseline, 1, 4, and 8 weeks. Baseline and follow-up front, and right and left lateral digital photographs were taken in the same photography room with identical lighting conditions by the investigator using a Nikon SLR 300 S and Nikkor 85 mm lens at ISO 800, 1/250 seconds, and aperture 4.0.

### Safety

Safety assessments were performed immediately post-illumination, and at each follow-up interval. Pain was assessed using the visual analog scale (VAS) and graded from 0 (no pain) to 10 (the worst pain imaginable). The local skin reaction was classified as mild (transient and easily tolerated), moderate (caused patient discomfort and interrupted usual activities), or severe (caused considerable interference with usual activities and may have been incapacitating or life threatening).

### Erythema/Dyspigmentation/Adverse Events Assessments

Erythema and hyperpigmentation intensities, and any other adverse events were assessed clinically by the investigator 1, 3, and 7 days post-treatment and at 4- and 8-week follow-up.

### Statistical Analysis

To investigate the efficacy of FxCO<sub>2</sub>-PDT in treating multiple facial AKs, the authors analyzed the differences in response, cosmetic outcomes, and local adverse events between the FxCO<sub>2</sub>-PDT and ALA-PDT groups at 15- and 30-minute ALA incubations, respectively. All statistical analyses are performed using the Statistical Package for Social Sciences software (version 18.00; SPSS, Inc, Chicago, IL). The categorical variables were analyzed using Pearson's chi-square test and Fisher exact test, and the continuous variables were analyzed using one-way analysis of variance and the Student *t* test and Wilcoxon sum-rank test. A *p* value <.05 was considered statistically significant. The sample size with a 95% confidence interval and a margin of error of 8

**TABLE 1. Patient Demographics and Lesion Counts**

	15 min ALA, +FxCO <sub>2</sub>	15 min ALA, -FxCO <sub>2</sub>	30 min ALA, +FxCO <sub>2</sub>	30 min ALA, -FxCO <sub>2</sub>
Mean (SD) age	64.20 (10.53)		65.10 (11.20)	
Mean (SD) baseline actinic keratosis count	25.70 (15.36)	24.70 (17.03)	18.60 (9.86)	19.10 (11.09)

ALA, aminolevulinic acid; SD, standard deviation.

was calculated at 150. In this study, the number of lesions in each study arm were: 186 (+F<sub>x</sub> 30'), 191 (-F<sub>x</sub> 30'), 257 (+F<sub>x</sub> 15'), and 247 (-F<sub>x</sub> 15').

**Results**

**Patient Demographics**

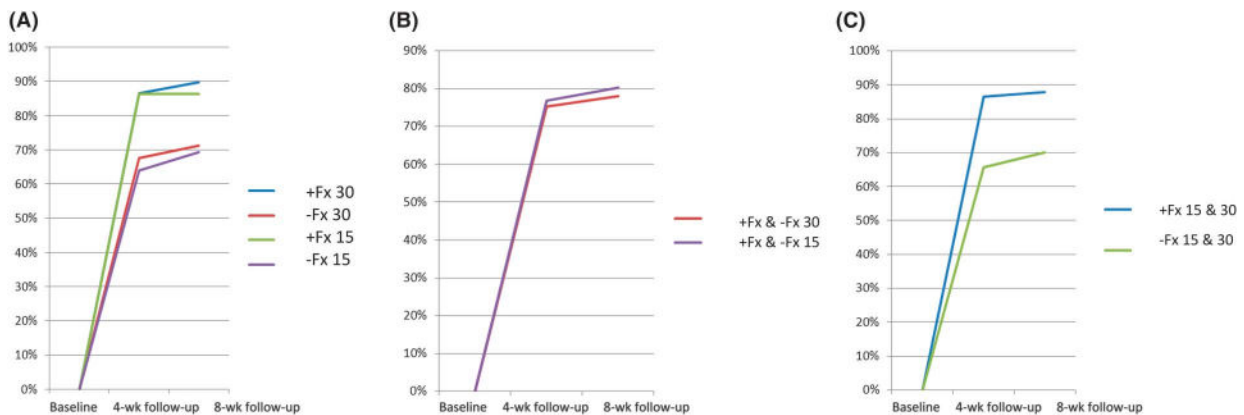
The mean (SD) age and baseline number (SD) of AK lesions for each randomized group and for each randomized side are shown in Table 1. Mean Age (SD) was 64.20 (10.53) and 65.10 (11.20) in the 15- and 30-minute incubation groups, respectively. AK counts at baseline were also comparable between the 2 randomized comparable paired groups and the 2 treatment arms (Table 1).

**Efficacy**

Actinic keratosis lesional clearance was classified as either complete response (complete disappearance of

the lesion) or noncomplete response (incomplete disappearance of the lesion). The CR was calculated as the percentage of lesions with complete disappearance at follow-up interval over baseline.

The complete CRs at 8 weeks after ALA PDT with and without F<sub>x</sub>CO<sub>2</sub> at 30- and 15-minute ALA incubation times were 89.78% (+F<sub>x</sub>CO<sub>2</sub>) versus 71.20% CR (-F<sub>x</sub>CO<sub>2</sub>) at 30', and 86.38% (+F<sub>x</sub>CO<sub>2</sub>) versus 69.23% (-F<sub>x</sub>CO<sub>2</sub>) at 15' ALA incubation (Figure 2A and Table 2). All lesion improvements were statistically significant (Table 2). Actinic keratosis CR at 4-week and 8-week follow-up was statistically significant for each one of the 4 groups of subjects (Table 2, A–D). Marked statistical significance of improvement was observed by 4-week follow-up for both groups of patients treated with +F<sub>x</sub>CO<sub>2</sub> laser irrespective of incubation time (Table 2, A and C). Statistical significance of improvement was much greater for both groups of subjects treated



**Figure 2.** Comparison of actinic keratosis (AK) clearance rate (CR) at baseline and 4- and 8-week follow-up from photodynamic therapy (PDT) at 15- and 30-minute incubations with and without F<sub>x</sub>CO<sub>2</sub>. (A) Comparison of AK CR for all treatment arms at each follow-up interval. The highest AK CR was for F<sub>x</sub>CO<sub>2</sub> 30-minute aminolevulinic acid (ALA) incubation PDT followed by F<sub>x</sub>CO<sub>2</sub> 15-minute ALA incubation, no F<sub>x</sub>CO<sub>2</sub> 30-minute ALA incubation and no F<sub>x</sub>CO<sub>2</sub> 15-minute ALA incubation. (B) Comparison of 15- and 30-minute ALA incubation times irrespective of F<sub>x</sub>CO<sub>2</sub>. Minimal difference was noted between the 2 incubation times when grouped. C. Comparison of +F<sub>x</sub>CO<sub>2</sub> versus -F<sub>x</sub>CO<sub>2</sub> groups irrespective of incubation time. The +F<sub>x</sub>CO<sub>2</sub> group yielded a higher AK clearance rate as compared to -F<sub>x</sub>CO<sub>2</sub> when both incubation times were grouped.

**TABLE 2. Actinic Keratosis Clearance Rate at 4- and 8-Week Follow-Up After ALA Photodynamic Therapy With and Without FxCO<sub>2</sub> Laser Resurfacing at 30- and 15-Minute ALA Incubation Times**

<i>A. +FxCO<sub>2</sub> and 30 min ALA Incubation Time</i>				
<i>No. of Lesions (10 Patients)</i>	<i>+FxCO<sub>2</sub> @ 30 min—Baseline</i>	<i>+FxCO<sub>2</sub> @ 30 min—4-wk Follow-Up</i>	<i>+FxCO<sub>2</sub> @ 30 min—8-wk Follow-Up</i>	
Mean	18.60	2.50	1.90	
SD	9.86	2.33	1.45	
Total	186	25	19	
Improvement, %	0	86.55	89.78	
<i>t</i> test: follow-up vs baseline	—	<i>p</i> < .0005	<i>p</i> < .0005	
Wilcoxon rank-sum test: follow-up vs baseline	—	<i>p</i> < .005	<i>p</i> < .005	
<i>B. -FxCO<sub>2</sub> and 30 min ALA Incubation Time</i>				
<i>No. of Lesions (10 Patients)</i>	<i>-FxCO<sub>2</sub> @ 30 min—Baseline</i>	<i>-FxCO<sub>2</sub> @ 30 min—4-wk Follow-Up</i>	<i>-FxCO<sub>2</sub> @ 30 min—8-wk Follow-Up</i>	
Mean	19.10	6.20	5.50	
SD	11.09	5.33	4.20	
Total	191	62	55	
Improvement, %	0	67.53	71.20	
<i>t</i> test: follow-up vs baseline	—	<i>p</i> < .001	<i>p</i> < .005	
Wilcoxon rank-sum test: follow-up vs baseline	—	<i>p</i> < .05	<i>p</i> < .01	
<i>C. +FxCO<sub>2</sub> and 15 min ALA Incubation Time</i>				
<i>No. of Lesions (10 Patients)</i>	<i>+FxCO<sub>2</sub> @ 15 min—Baseline</i>	<i>+FxCO<sub>2</sub> @ 15 min—4-wk Follow-Up</i>	<i>+FxCO<sub>2</sub> @ 15 min—8-wk Follow-Up</i>	
Mean	25.70	3.50	3.50	
SD	15.36	4.70	4.92	
Total	257	35	35	
Improvement, %	0	86.38	86.38	
<i>t</i> test: follow-up vs baseline	—	<i>p</i> < .0005	<i>p</i> < .0005	
Wilcoxon rank-sum test: follow-up vs baseline	—	<i>p</i> < .005	<i>p</i> < .001	
<i>D. -FxCO<sub>2</sub> and 15 min ALA Incubation Time</i>				
<i>No. of Lesions (10 Patients)</i>	<i>-FxCO<sub>2</sub> @ 15 min—Baseline</i>	<i>-FxCO<sub>2</sub> @ 15 min—4-wk Follow-Up</i>	<i>-FxCO<sub>2</sub> @ 15 min—8-wk Follow-Up</i>	
Mean	24.70	8.90	7.60	
SD	17.03	7.96	6.99	
Total	247	89	76	
Improvement, %	0	63.96	69.23	
<i>t</i> test: follow-up vs baseline	—	<i>p</i> < .005	<i>p</i> < .005	
Wilcoxon rank-sum test: follow-up vs baseline	—	<i>p</i> < .05	<i>p</i> < .05	

Statistical significance of improvement at 4-week and 8-week follow-up per incubation time.

+FxCO<sub>2</sub>, with fractional CO<sub>2</sub> laser resurfacing; -FxCO<sub>2</sub>, without fractional CO<sub>2</sub> laser resurfacing; ALA, aminolevulinic acid; SD, standard deviation.

with FxCO<sub>2</sub> laser (regardless of incubation time) than for both groups of subjects not treated with FxCO<sub>2</sub> laser (regardless of incubation time) (Table 2, B and D). The differences in AK between the +FxCO<sub>2</sub> and –FxCO<sub>2</sub> cohorts treated at 15-minute ALA incubation were statistically significant at 4-week and 8-week follow-ups (Table 5, A). The differences in AK CR between the +FxCO<sub>2</sub> and –FxCO<sub>2</sub> cohorts treated at 30-minute ALA incubation were also statistically significant at 4-week and 8-week follow-ups (Table 5, B).

Comparison of the +FxCO<sub>2</sub> and –FxCO<sub>2</sub> cohorts irrespective and grouping of subjects treated at both ALA incubation times demonstrated statistically significant greater improvement for the +FxCO<sub>2</sub> (15 and 30 minutes) cohort at AK CR of 86.45% and 87.81% at 4- and 8-week follow-ups, respectively, as compared to 65.52% and 70.09% for the –FxCO<sub>2</sub> (15 and 30 minutes) cohort, respectively (Figure 2B and Table 3, A and B).

Marked statistical significance was observed for both groups (Table 3, A and B).

Comparison of the 15- versus 30-minute ALA incubation time cohorts, irrespective of antecedent FxCO<sub>2</sub> treatment, demonstrated 76.92% and 80.37% AK CR at 4- and 8-week follow-ups, respectively for the 30' ALA incubation cohort (Figure 2C and Table 4, A); these values were 75.39% and 77.98%, respectively, for the 15' ALA incubation cohort (Table 3, B). Although the AK CR for each cohort was highly statistically significant, there was not statistically significant difference between the different incubation times, whether or not FxCO<sub>2</sub> treatment was administered.

**Cosmesis**

The degree of cosmetic improvement in photoaging at 8 weeks was rated higher on the FxCO<sub>2</sub>-treated side in all subjects. The average rating was excellent

**TABLE 3. Comparison of Actinic Keratosis Clearance Rate From ALA Photodynamic Therapy With and Without FxCO<sub>2</sub> Laser Resurfacing**

*A. Statistical Significance of Improvement at 4- and 8-wk Follow-Up. +FxCO<sub>2</sub> Regardless of Incubation Time*

No. of Lesions (20 Patients)	+FxCO <sub>2</sub> @ 15 and 30 min—Baseline	+FxCO <sub>2</sub> @ 15 and 30 min—4-wk Follow-Up	+FxCO <sub>2</sub> @ 15 and 30 min—8-wk Follow-Up
Mean	22.15	3.00	2.70
SD	13.38	3.74	3.72
Total	443	60	54
Improvement, %	0	86.45	87.81
t test: follow-up vs baseline	—	p < .0001	p < .0001
Wilcoxon rank-sum test: follow-up vs baseline	—	p < .0001	p < .0001

*B. Statistical Significance of Improvement at 4- and 8-wk Follow-Up. –FxCO<sub>2</sub> Regardless of Incubation Time*

No. of Lesions (20 Patients)	–FxCO <sub>2</sub> @ 15 and 30 min—Baseline	–FxCO <sub>2</sub> @ 15 and 30 min—4-wk Follow-Up	–FxCO <sub>2</sub> @ 15 and 30 min—8-wk Follow-Up
Mean	21.90	7.55	6.55
SD	14.64	6.90	5.86
Total	438	151	131
Improvement, %	0	65.52	70.09
t test: follow-up vs baseline	—	p < .0001	p < .0001
Wilcoxon rank-sum test: follow-up vs baseline	—	p < .0001	p < .0001

ALA, aminolevulinic acid; SD, standard deviation.

**TABLE 4. Comparison of Actinic Keratosis Clearance Rate From ALA Photodynamic Therapy at 15- Versus 30-Minute ALA Incubation Times****A. Statistical Significance of Improvement at 4- and 8-wk Follow-Up. All Patients with 30 min Incubation Time, Regardless of Tx Method**

No. of Lesions (20 Patients)	+FxC <sub>2</sub> O <sub>2</sub> and –FxC <sub>2</sub> O <sub>2</sub> @ 30 min—Baseline	+FxC <sub>2</sub> O <sub>2</sub> and –FxC <sub>2</sub> O <sub>2</sub> @ 30 min—4-wk Follow-Up	+FxC <sub>2</sub> O <sub>2</sub> and –FxC <sub>2</sub> O <sub>2</sub> @ 30 min—8-wk Follow-Up
Mean	18.85	4.35	3.70
SD	10.49	4.51	3.62
Total	377	87	74
Improvement, %	0	76.92	80.37
t test: follow-up vs baseline	—	<i>p</i> < .0001	<i>p</i> < .0001
Wilcoxon rank-sum test: follow-up vs baseline	—	<i>p</i> < .0001	<i>p</i> < .0001

**B. Statistical Significance of Improvement at 4- and 8-wk Follow-Up. All Patients with 15 min Incubation Time, Regardless of Tx Method**

No. of Lesions (20 Patients)	+FxC <sub>2</sub> O <sub>2</sub> and –FxC <sub>2</sub> O <sub>2</sub> @ 15 min—Baseline	+FxC <sub>2</sub> O <sub>2</sub> and –FxC <sub>2</sub> O <sub>2</sub> @ 15 min—4-wk Follow-Up	+FxC <sub>2</sub> O <sub>2</sub> and –FxC <sub>2</sub> O <sub>2</sub> @ 15 min—8-wk Follow-Up
Mean	25.20	6.20	5.55
SD	16.22	7.07	6.38
Total	504	124	111
Improvement, %	0	75.39	77.98
t test: follow-up vs baseline	—	<i>p</i> < .0001	<i>p</i> < .0001
Wilcoxon rank-sum test: follow-up vs baseline	—	<i>p</i> < .0001	<i>p</i> < .0001

Improvement at 4-week follow-up and 8-week follow-up is greatly statistically significant, for each 1 of the 4 groups of patients.

Great statistical significance of improvement by 4-week follow-up for each group of subjects (i.e., regardless of incubation time and Tx method).

ALA, aminolevulinic acid; SD, standard deviation.

on the FxC<sub>2</sub>O<sub>2</sub> side and good on the ALA PDT side. No incidence of scarring or worsening of pigmentation was observed. Photographic examples of representative before-and-after photographs are shown in Figures 3–5.

### Safety

Safety assessments were performed immediately postillumination, and at each follow-up interval. Pain was assessed using the VAS and graded from 0 (no pain) to 10 (the worst pain imaginable). The local skin reaction was classified as mild (transient and easily tolerated), moderate (caused patient discomfort and interrupted usual activities), or severe (caused considerable interference with usual

activities and may have been incapacitating or life threatening). An example of post-treatment erythema is shown in Figure 5.

Pain assessed by VAS scale was an average of 4 on the FxC<sub>2</sub>O<sub>2</sub>-treated side and 3 on the contralateral ALA PDT alone side during illumination. On the randomized side of the face treated with ALA-PDT alone, minimal-to-moderate post-treatment erythema resolved within 5 days in all subjects. On the paired side treated with FxC<sub>2</sub>O<sub>2</sub>-ALA-PDT, the erythema was rated as moderate-to-significant and resolved within 5 to 7 days (Figure 5). No incidence of infection, dyspigmentation, or scarring was observed. No severe adverse events were reported or observed at the follow-up intervals.

**TABLE 5. Comparison of AK CR With and Without Previous Treatment With Fractional Ablative Laser Resurfacing and ALA or MAL PDT**

*A. Previous Published Reports of AK CR With and Without Antecedent Fractional Resurfacing*

Study	Indication	Fx Laser	Photosensitizer	Incubation Time	Light Source	Clearance Rates +/- Fx, %	Follow-Up, m
Jang and colleagues <sup>16</sup>	AK face	CO <sub>2</sub>	ALA	70–90 m +Fx no control	Red	70.6	2
Helsing and colleagues <sup>13</sup>	AK hands	CO <sub>2</sub>	MAL	3 h +Fx 0 h +Fx	Red	73 31	4
Ko and colleagues <sup>14</sup>	AK face	Er: YAG	MAL	3 h +Fx 3 h –Fx	Red	86.9 61.2	1
Choi and colleagues <sup>15</sup>	AK face, scalp	Er: YAG	MAL	3 h +Fx 2 h +Fx 3 h –Fx	Red	91.7 76.8 65.6	3
Togsverd-Bo and colleagues, 2015	AK scalp, chest, extremities	Er: YAG	MAL	2.5 h +Fx 2.5 h –Fx	Daylight	74 46	3

*B. Comparison of Reported Head AK CR Ranges From Published and Current Reports With (+) and Without (–) Previous Fractional Ablative Resurfacing for MAL Red Light and ALA PDT Blue Light*

Protocol	– Fx, %	+Fx, %
MAL red light 3 h trials	67–89 <sup>20,21</sup>	NA
ALA blue light 14–18 h trials	88–89 <sup>3,4</sup>	NA
MAL red light PDT 3 h	61.2–65.6 <sup>13,14</sup>	86.9–91.7 <sup>13,14</sup>
ALA blue light PDT 15–30'	69.2–71.2 (current findings)	86.4–89.8 (current findings)

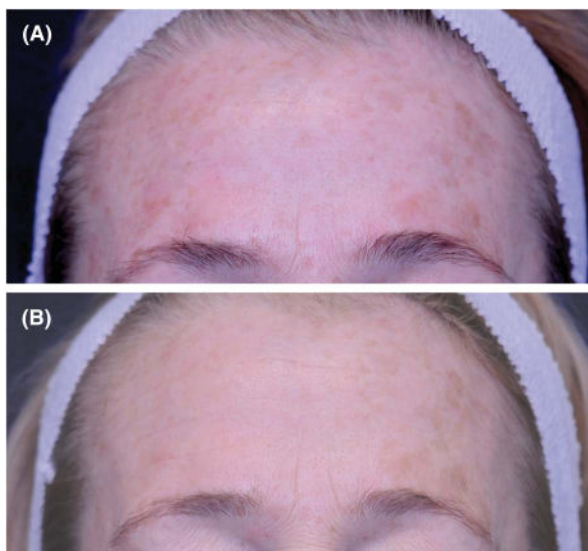
AK, actinic keratosis; ALA, aminolevulinic acid; CR, clearance rate; MAL, methyl aminolevulinate; PDT, photodynamic therapy.

**Discussion**

It has been presumed that PDT efficacy is largely dependent on protoporphyrin IX (PPIX) accumulation, which occurs over the course of hours after ALA application, reaching its maximum at 14 to 18 hours<sup>17</sup> PDT with topical 20% ALA at 14- to 18-hour incubation times and blue light irradiation for the treatment of AK yielded CR of 88% at 8-week follow-up; 89% at 3-month follow-up; and 78% after 2 treatments at 12-month follow-up.<sup>3–5</sup> In 2003, the author and colleague were the first to report that shorter ALA incubation time of 3 hours followed by pulsed dye laser was effective at AK clearance with 90%, 70%, and 65% CR for head, extremities, and trunk lesions, respectively.<sup>18</sup> Subsequently, other investigators reproduced these findings with AK CR for head lesions of 93%, 84%, and 90% after 1, 2, and 3 hours of ALA

incubations, respectively, with blue light at 1-month follow-up.<sup>8</sup> A more recent study showed 68% to 79% AK CR after 1, 2, or 3 hours of ALA and blue light.<sup>9</sup> A fluorescence kinetics study reported a linear accumulation of PPIX over time that became statistically higher than background in 48% of AK by 20 minutes, 92% by 1 hour, and 100% of lesions by 2 hours after ALA application.<sup>6</sup> This study is the first to compare the safety and efficacy of ultrashort 15- and 30-minute ALA incubations followed by blue light PDT with or without antecedent FxCO<sub>2</sub> treatment in a split-face paired group comparison. Ultrashort incubations yielded statistically significant AK CR of 69.23% after 15' and 71.20% after 30' ALA incubation. Pre-treatment with FxCO<sub>2</sub> increased AK CR to 86.38% after 15' and 89.78% after 30' ALA incubation, with differences that were statistically significant as

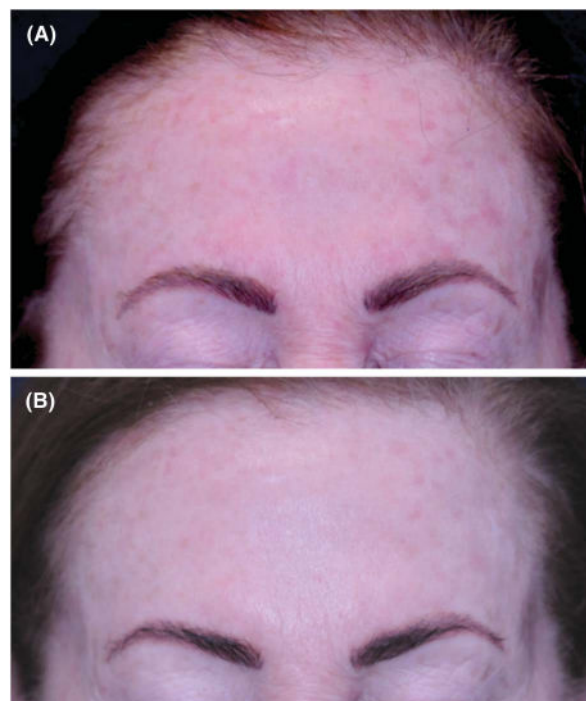




**Figure 3.** Baseline and 8-week follow-up of subject randomized to pretreatment with FxCO<sub>2</sub> to Right and 30-minute aminolevulinic acid incubation with blue light. The 2 sides of the face display comparable actinic keratosis (AK) counts and photodamage at baseline (left). Greater improvement in AK clearance rate and post-treatment cosmesis is evident on the right in the post-treatment photograph (right).

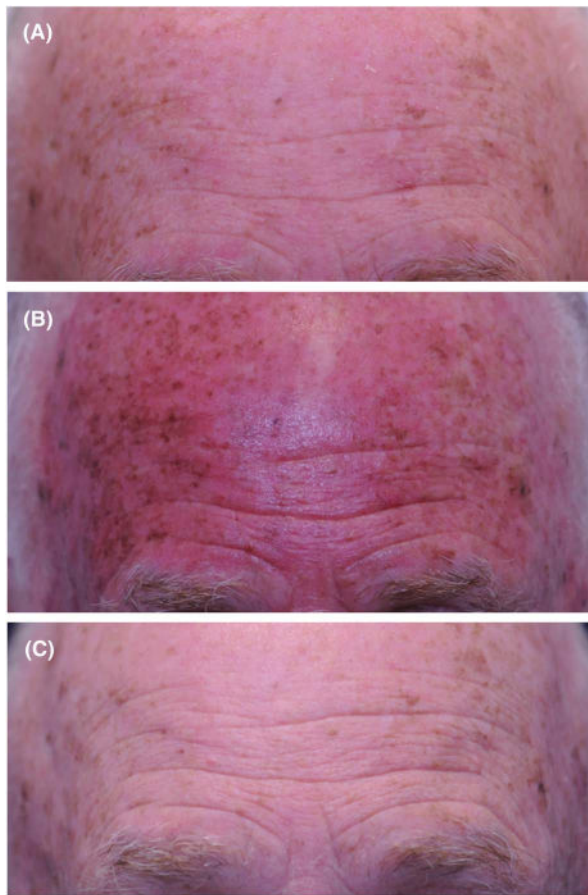
compared to paired controls. The findings reported here suggest that ultrashort incubations of 15 and 30 minutes followed by blue light are adequate for a PDT response and AK clearance; however, pretreatment with FxCO<sub>2</sub> greatly enhanced AK CR for both groups.

The application of fractional ablative lasers to increase PDT efficacy has been theorized to be due to increased photosensitizer delivery. An increase in fluorescence intensities at the skin surface and at greater skin depths have been shown after FxCO<sub>2</sub>-assisted MAL application as compared to MAL alone.<sup>12</sup> Intensities were 66.6 versus 1.0 at 120  $\mu$ m and 35.4 versus 1.2 at 1800  $\mu$ m depth, with and without pretreatment with FxCO<sub>2</sub>, respectively.<sup>12</sup> These findings indicate that FxCO<sub>2</sub> before MAL application greatly increased photosensitizer delivery throughout the epidermis and superficial dermis. It was also shown that FxCO<sub>2</sub> greatly enhanced fluorescence intensities after short 30-minute incubation ALA in the porcine model of 14.1 au.<sup>11</sup> The latter findings suggested that pretreatment with FxCO<sub>2</sub> may facilitate enhanced photosensitizer delivery at shorter incubation times. Concurrently, a series of clinical studies have



**Figure 4.** Baseline and 8-week follow-up of subject randomized to pretreatment with FxCO<sub>2</sub> to Left and 15-minute aminolevulinic acid incubation with blue light. The 2 sides of the face display comparable actinic keratosis (AK) counts and photodamage at baseline (left). Greater improvement in AK clearance rate and post-treatment cosmesis is evident on the left in the post-treatment photograph (right).

demonstrated higher AK CR with fractional ablative laser pretreatment; however, all but one of these studies examined MAL PDT.<sup>12-16</sup> The AK CRs from MAL PDT clinical trials and the control cohorts in randomized studies were 67% to 89%<sup>19-21</sup>; in contrast, with fractional ablative laser pretreatment, the values were 87% to 92% at follow-up times of 1 to 4 months (Table 5).<sup>13,14</sup> The aforementioned studies support the theory that fractional laser pretreatment increases MAL PDT efficacies through increased drug delivery; however, until now, data on the impact of pretreatment with fractional lasers on ALA PDT had been lacking (Table 5, A). A single pilot study comparing FxCO<sub>2</sub>-assisted PDT with ALA versus MAL and short 70- to 90-minute incubations demonstrated comparable AK CR when red light was used.<sup>16</sup> In that study, 17 AK lesions were treated with FxCO<sub>2</sub>, 90-minute ALA incubation, and red light PDT. At 8-week follow-up, AK CR, which was calculated in a manner consistent with this study, was reported at 88.2%



**Figure 5.** Postoperative recovery after +/- FxCO<sub>2</sub> aminolevulinic acid (ALA) photodynamic therapy. The baseline, 1-day and 8-week follow-up photographs from a subject randomized to pretreatment with FxCO<sub>2</sub> to the right and 30 minutes ALA blue light treatment. (A) Baseline: Demonstrating actinic keratosis (AK) on forehead. (B) One day postoperative: demonstrating moderate erythema which is more prominent on the right. (C) Eight-week follow-up: demonstrating greater AK clearance rate on right versus left.

although red light was used.<sup>16</sup> On tabulating head AK CR without versus with pretreatment with fractional ablative lasers from the previous and current randomized trials, the comparisons are 61.2% to 65.6% versus 86.9% to 91.7% for 3-hour MAL red light PDT; and 69.2% to 71.2% versus 86.4% to 89.8% for 15- to 30-minute ALA blue light PDT (Table 5, B). The findings reported here provide the first data set on the impact of fractional ablative laser pretreatment on ALA blue light PDT efficacy.

The theory of enhanced photosensitizer delivery because of a dose-dependent delivery and PPIX accumulation in keratinocytes seems to be incomplete, as

subcellular localization has been shown to play an even more critical role in PDT efficacy. Subcellular localization of photosensitizers can be highly specific or quite broad, and has been reported to include the endoplasmic reticulum (ER), mitochondria, Golgi, lysosomes, and plasma membrane.<sup>22,23</sup> The initial cellular localization of PPIX after ALA application has been demonstrated to be restricted to the mitochondria.<sup>24-26</sup> It has been further shown that initial PPIX-mediated photodynamic damage is localized to the mitochondria.<sup>26,27</sup> Ensuing apoptosis has been reported to occur within 10 hours.<sup>28</sup> The intracellular localization and concentrations of protoporphyrins are determined by at least 3 rate-limiting steps: ALA uptake through proton-coupled oligopeptide transporters, such as PEPT1 and PEPT2, conversion of PpIX to heme through ferrochelatase, FECH, and intracellular transfer of PpIX through ATP-binding cassette (ABC) transporter G2 (ABCG2), the latter of which inversely impacts ALA-induced PPIX accumulation.<sup>29</sup> Although photodynamic inactivation of different cancer cells seemed to be directly related to PPIX accumulation, examination of the data in more detail has revealed that photodynamic efficacy per photosensitizer molecule differs dramatically in different systems and relates directly to the different intracellular location of PPIX.<sup>30</sup> Thus, enhancement of photodynamic efficacy by facilitated photosensitizer delivery is not linked to increased concentration of photosensitizer precursor in the target tissue, but rather to the subcellular localization of downstream photosensitizer, namely, mitochondrial localization of ALA-induced PPIX in the case of AK.

The mechanism of action of short incubation ALA-PDT is a matter of great interest. In AKs, ultraviolet B inactivation of the tumor-suppressor p53, which maintains a stable genome through its role in promoting cell-cycle checkpoints, DNA repair, and apoptosis, results in genomic instability.<sup>28</sup> Gain-of-function mutations in *Ras*, *Fyn/SFKs*, and *Bcl-2* have been demonstrated in AK.<sup>31</sup> *Bcl-2* overexpression in AK has also been well demonstrated.<sup>30</sup> Because *Bcl-2* inhibits apoptosis, it is a prime target for cancer therapy, and PDT selectively destroys *Bcl-2*.<sup>32,33</sup> Moreover, enhanced apoptotic response to PDT has been observed after *Bcl-2* transfection/upregulation, and

Bcl-2 expression is associated with favorable response to PDT.<sup>34,35</sup> Experimental studies have shown that PDT induces selective degradation of the Bcl-2 protein, leading to apoptosis by decreasing the Bcl-2/Bax ratio.<sup>36</sup> The proapoptotic Bax and BH3-only proteins mediate mitochondrial disruption and detect developmental death cues downstream of Bcl-2 damage.<sup>37</sup> Bcl-2 proteins control cytochrome c release: PDT targeting of Bcl-2 triggers mitochondrial membrane permeability transition pores to open, releasing cytochrome c into the cytosol and triggering the caspase pathway of apoptotic cell death.<sup>37</sup> Caspase-independent pathways of cell death may also occur, including necrosis and autophagy after PDT; however, these have yet to be rigorously demonstrated in ALA PDT-mediated cell death pathways in AK.<sup>37</sup>

Although cell death pathways such as necrosis and autophagy may also play a role, the author theorizes that ultrashort ALA incubation in the PDT response in AK seems to primarily involve mitochondrial localization, targeting of bcl-2 and triggering of apoptosis. In support of this theory, the initial localization of ALA-induced PPIX is in the mitochondrion; the antiapoptotic protein Bcl-2 is a target of ALA PDT, and the apoptotic response is activated by ALA PDT and greatly increased by Bcl-2 overexpression.<sup>20–27,29–32,38</sup> Since linear PPIX accumulation over time has been shown to be higher than background in only 48% of AK by 20 minutes, intracellular accumulation of ALA-induced photosensitizer after ultrashort incubations does not fully account for the photodynamic efficacy reported here which reached roughly 69% to 71% CR for AK treated with blue light alone.<sup>12</sup> The PDT efficacy demonstrated here after ultrashort ALA incubation may be explained by rapid ALA-induced mitochondrial PPIX accumulation and apoptotic pathway triggering, rather than purely a dose-dependent increase in ALA concentration in skin. Thus, while AK CR may be directly related to PPIX accumulation, the efficacy after ultrashort ALA incubation reported here also suggests that photodynamic efficacy per photosensitizer molecule may relate to the intracellular location of PPIX as opposed to net dose of PPIX. Comparatively greater PDT efficacy from pretreatment with fractional CO<sub>2</sub> resurfacing may relate not only to a dose-dependent increase in photosensitizer

delivery, as has been shown previously but also to a greater subcellular localization of ALA-induced PPIX in mitochondria, a hypothesis that is deserving of direct study.

Limitations of the conclusions put forth herein include the possibility that the parameters used for the fractional CO<sub>2</sub> laser itself may have contributed to the increased CRs at the density used without positing increased photosensitizer delivery. An alternative potential confounder is that the heat generated from the laser may increase ALA conversion to PPIX, absorption of ALA or increase penetration.

## Conclusion

In this randomized, blinded, paired-design, controlled clinical trial of FxCO<sub>2</sub>-assisted ultrashort incubation ALA PDT for the treatment of AK, photodynamic efficacy is demonstrated at 15- and 30-minute ALA incubations. Pretreatment with fractional ablative resurfacing augments ALA-PDT efficacy for AK clearance at ultrashort ALA incubations followed by blue light.

## References

1. Criscione VD, Weinstock MA, Naylor MF, et al. Actinic keratoses: natural history and risk of malignant transformation in the veterans affairs topical tretinoin chemoprevention trial. *Cancer* 2009;116:2523–30.
2. Werner RN, Sammain A, Erdmann R, Hartmann V, et al. The natural history of actinic keratosis: a systematic review. *Br J Dermatol* 2013;169:502–18.
3. Jeffes EW, McCullough JL, Weinstein GD, et al. Photodynamic therapy of actinic keratoses with topical aminolevulinic acid hydrochloride and fluorescent blue light. *J Am Acad Dermatol* 2001;45:96–104.
4. Piacquadro DJ, Chen DM, Farber HF, et al. Photodynamic therapy with aminolevulinic acid topical solution and visible blue, light in the treatment of multiple actinic keratoses of the face and scalp—investigator-blinded, phase 3, multicenter trials. *Arch Dermatol* 2004;140:41–6.
5. Tschien EH, Wong DS, Pariser DM, et al. Photodynamic therapy using aminolevulinic acid for patients with nonhyperkeratotic actinic keratoses of the face and scalp: phase IV multicentre clinical trial with 12-month follow up. *Br J Dermatol* 2006;155:1262–9.
6. Warren CB, Lohser A, Wene LC, Pogue BW, et al. Noninvasive fluorescence monitoring of protoporphyrin IX production and clinical outcomes in actinic keratoses following short-contact application of 5-aminolevulinic acid. *J Biomed Opt* 2010;15:051607.
7. Smith S, Piacquadro D, Morhenn V, Atkin D, et al. Short incubation PDT versus 5-FU in treating actinic keratoses. *J Drugs Dermatol* 2003;2:629–3.

8. Touma D, Yaar M, Whitehead S, Konnikov N, et al. A trial of short incubation, broad-area photodynamic therapy for facial actinic keratoses and diffuse photodamage. *Arch Dermatol* 2004;140:33–40.
9. Pariser DM, Houlihan A, Ferdon MB, Berg JE; PDT-AK Investigational Group. Randomized vehicle-controlled study of short drug incubation aminolevulinic acid photodynamic therapy for actinic keratoses of the face or scalp. *Dermatol Surg* 2016;42:296–304.
10. Gerritsen MJP, Smits T, Kleipenning MM, et al. Pretreatment to enhance protoporphyrin IX accumulation in photodynamic therapy. *Dermatology* 2009;218:193–02.
11. Haedersdal M, Sakamoto FH, Farinelli WA, Doukas AG, et al. Pretreatment with ablative fractional laser changes kinetics and biodistribution of topical 5-aminolevulinic acid (ALA) and methyl aminolevulinate (MAL). *Lasers Surg Med* 2014;46:462–9.
12. Helsing P, Togsverd-Bo K, Velerod MB, Mork G, et al. Intensified fractional CO<sub>2</sub> laser-assisted photodynamic therapy vs. laser alone for organ transplant recipients with multiple actinic keratosis and wart-like lesions in a randomized half-side comparative trial on dorsal hands. *Br J Dermatol* 2013;169:1087–92.
13. Ko DY, Jeon SY, Kim KH, Song KH. Fractional erbium: YAG laser-assisted photodynamic therapy for facial actinic keratoses: a randomized, comparative, prospective study. *J Eur Acad Dermatol Venereol* 2014;28:1529–39.
14. Choi SH, Kim KH, Song KH. Efficacy of ablative fractional laser-assisted photodynamic therapy with short-incubation time for the treatment of facial and scalp actinic keratosis: 12-month follow-up results of a randomized, prospective, comparative trial. *J Eur Acad Dermatol Venereol* 2015;29:1598–605.
15. Togsverd-Bo K, Lei U, Erlendsson AM, Taudorf EH, et al. Combination of ablative fractional laser and daylight mediated photodynamic therapy for actinic keratosis in organ transplant recipients—a randomized controlled trial. *Br J Dermatol* 2015;172:467–74.
16. Jang YH, Lee DJ, Shin J, Kang HY, et al. Photodynamic therapy with ablative carbon dioxide fractional laser in treatment of actinic keratosis. *Ann Dermatol* 2013;25:417–22.
17. DUSA Pharmaceuticals. “Levulan Kerastick topical solution 20%,” package insert. Available from: <http://www.dusapharma.com>. Accessed June 7, 2009.
18. Alexiades-Armenakas MR, Geronemus RG. Laser-mediated photodynamic therapy of actinic keratoses. *Arch Dermatol* 2003;139:1313–20.
19. Tarstedt M, Rosdahl I, Berne B, Svanberg K, Wennberg A-M. A randomized multicenter study to compare two treatment regimens of topical methyl aminolevulinate (MetvixH)-PDT in actinic keratosis of the face and scalp. *Acta Derm Venereol* 2005;85:424–8.
20. Szeimies RM, Matheson RT, Davis SA, Bhatia AC, et al. Topical methyl aminolevulinate photodynamic therapy using red light-emitting diode light for multiple actinic keratoses: a randomized study. *Dermatol Surg* 2009;35:586–92.
21. Morton C, Campbell S, Gupta G, Keohane S, et al; AKtion Investigators. Intraindividual, right-left comparison of topical methyl aminolevulinate-photodynamic therapy and cryotherapy in subjects with actinic keratoses: a multicentre, randomized controlled study. *Br J Dermatol* 2006;155:1029–36.
22. Kessel D, Luo Y, Deng Y, Chang CK. The role of subcellular localization in initiation of apoptosis by photodynamic therapy. *Photochem Photobiol* 1997;65:422–6.
23. Kessel D. Correlation between subcellular localization and photodynamic efficacy. *J Porphyr Phthalocyanines* 2004;8:1009–14.
24. Peng Q, Moan J, Warloe T, et al. Distribution and photosensitizing efficiency of porphyrins induced by application of exogenous 5-aminolevulinic acid in mice bearing mammary carcinoma. *Int J Cancer* 1992;52:433–43.
25. Iinuma S, Farshi SS, Ortel B, et al. A mechanistic study of cellular photodestruction with 5-aminolevulinic acid-induced porphyrin. *Br J Cancer* 1994;70:21–8.
26. Ji Z, Yang G, Vasovic V, Cunderlikova B, et al. Subcellular localization pattern of protoporphyrin IX is an important determinant for its photodynamic efficiency of human carcinoma and normal cell lines. *J Photochem Photobiol B* 2006;84:213–20.
27. Oleinick N, Kim J, Rodriguez M, Xue LY; et al. Identifying initial molecular targets of PDT: protein and lipid oxidation products. *Proc SPIE 7380, Photodynamic Therapy: Back to the Future*, 738008, July 1, 2009.
28. Webber J, Luo Y, Crilly R, et al. An apoptotic response to photodynamic therapy with endogenous protoporphyrin in vivo. *J Photochem Photobiol B* 1996;35:209–11.
29. Kobuchi H, Moriya K, Ogino T, Fujita H, et al. Mitochondrial localization of ABC transporter ABCG2 and its function in 5-aminolevulinic acid-mediated protoporphyrin IX accumulation. *PLoS One* 2012;7:e50082.
30. Sailer R, Strauss WS, Wagner M, Emmert H, et al. Relation between intracellular location and photodynamic efficacy of 5-aminolevulinic acid-induced protoporphyrin IX in vitro. Comparison between human glioblastoma cells and other cancer cell lines. *Photochem Photobiol Sci* 2007;6:145–51.
31. Ratushny V, Gober MD, Hick R, Ridky TW, Seykora JT. From keratinocyte to cancer: the pathogenesis and modeling of cutaneous squamous cell carcinoma. *J Clin Invest* 2012;122:464–72.
32. Kang MH, Reynolds CP. Bcl-2 inhibitors: targeting mitochondrial apoptotic pathways in cancer therapy. *Clin Cancer Res* 2009;15:1126–32.
33. Usuda J, Chiu S, Azizuddin K, Xue L, et al. Promotion of photodynamic therapy-induced apoptosis by the mitochondrial protein Smac/DIABLO: dependence on Bax. *Photochem Photobiol* 2002;76:217–23.
34. Kim HR, Luo Y, Li G, Kessel D. Enhanced apoptotic response to photodynamic therapy after bcl-2 transfection. *Cancer Res* 1999;59:3429–32.
35. Koukourakis MI, Corti L, Skarlatos J, Giatromanolaki A, et al. Clinical and experimental evidence of Bcl-2 involvement in the response to photodynamic therapy. *Anticancer Res* 2001;21:663–8.
36. Casas A, Di Venosa G, Hasan T, Batlle A. Mechanisms of resistance to photodynamic therapy. *Curr Med Chem* 2011;18:2486–515.
37. Mroz P, Yaroslavsky A, Kharkwal GB, Hamblin MR. Cell death pathways in photodynamic therapy of cancer. *Cancers* 2011;3:2516–39.
38. Hanel W, Moll UM. Links between mutant p53 and genomic instability. *J Cell Biochem* 2012;113:433–9.

---

Address correspondence and reprint requests to: Macrene Alexiades, MD, PhD, Dermatology and Laser Surgery Center, 955 Park Avenue, New York, NY 10028, or e-mail: [dralexiaades@nyderm.org](mailto:dralexiaades@nyderm.org)