

# Multipass low fluence, high-frequency 755-nm alexandrite laser versus high fluence, low-frequency 1064-nm long-pulsed Nd: YAG laser in axillary hair reduction of dark skin phototypes: an intra-individual randomized comparative study

Nayera Mofteh, Mai Tymour & Shady Mahmoud Attia Ibrahim

To cite this article: Nayera Mofteh, Mai Tymour & Shady Mahmoud Attia Ibrahim (2021): Multipass low fluence, high-frequency 755-nm alexandrite laser versus high fluence, low-frequency 1064-nm long-pulsed Nd: YAG laser in axillary hair reduction of dark skin phototypes: an intra-individual randomized comparative study, Journal of Dermatological Treatment, DOI: [10.1080/09546634.2021.1914311](https://doi.org/10.1080/09546634.2021.1914311)

To link to this article: <https://doi.org/10.1080/09546634.2021.1914311>



Accepted author version posted online: 12 Apr 2021.



Submit your article to this journal [↗](#)



View related articles [↗](#)



View Crossmark data [↗](#)



**Multipass low fluence, high-frequency 755-nm Alexandrite laser versus high fluence, low-frequency 1064-nm long-pulsed Nd: YAG laser in axillary hair reduction of dark skin phototypes: An intra-individual randomized comparative study.**

**Nayera Moftah, MD, DTQM, DHPE**

*Ex. Dean of Faculty of Medicine for Girls, Al-Azhar University, Cairo, Egypt*

*Professor of Dermatology & Venereology, Faculty of Medicine for Girls, Al-Azhar University*

*Editor in Chief of Journal of the Egyptian Women's Dermatologic Society (JEWDS)*

*www.jewd.eg.net*

*Cellphone: +201222117774*

*nayeramoftah@hotmail.com*

**Mai Tymour**

*M.B.B.Ch of General Medicine & Surgery, Faculty of Medicine, Cairo University, Giza, Egypt*

*Diplomate of Dermatology & Venereology, Al-Azhar university, Cairo, Egypt*

*maitymour2790@icloud.com*

**Shady Mahmoud Attia Ibrahim**

*Assistant Professor of Dermatology & Venereology, Faculty of Medicine, Al-Azhar University, Cairo, Egypt*

**Corresponding author:** Shady Mahmoud Attia Ibrahim. **Mobile:** +2 01005367431.

**Email:** drshadyaly@yahoo.com, drshadyaly@azhar.edu.eg

I have no conflict of interest.

**Title: Multipass low fluence, high-frequency 755-nm Alexandrite laser versus high fluence, low-frequency 1064-nm long-pulsed Nd: YAG laser in axillary hair reduction of dark skin phototypes: An intra-individual randomized comparative study**

Running title: 755 versus 1064 nm lasers in axillary hair reduction

## ABSTRACT

Background: Laser hair removal has become popular means of achieving hair reduction with improved quality of life.

Objective: This study aimed to assess the safety and efficacy of Multipass low fluence, high-frequency 755-nm Alexandrite laser versus the high fluence, low-frequency 1064-nm long-pulsed Nd: YAG laser on axillary hair reduction in women with dark skin phototypes.

Patients and Methods: This study was carried out on 30 adult women [skin type, IV-VI] who seek axillary hair reduction. These subjects were adjusted to receive 5 laser sessions with a 1-month interval. One side received high fluence, low-frequency 1064-nm laser where the other side received multipass low fluence, high-frequency 755 nm laser. The follow up was done using photographs, folliscope, patients' visual analog pain scale.

Results: The mean percentage of hair density reduction showed significant improvement in both treated sides being higher in the Alex treated side with corresponding significant decreases in the mean hair thickness..

Conclusion: Multipass low fluence, high-frequency 755-nm Alex laser practice was verified to be safe and effective for hair removal in dark skin phototypes compared to the high fluence, low frequency 1064-nm long pulsed Nd:YAG laser.

Keywords: hair removal; axillary hair; Alexandrite laser; long-pulsed Nd-YAG laser; dark skin

## Introduction

Several studies displayed that social fear in women with unwanted hair could influence their participation in their social as well as interpersonal activities where different modalities for hair removal were introduced including laser [1,2]. Laser hair removal is accomplished through the destruction of the follicular unit without damaging the nearby skin [3,4]. Besides, it provides hair-free intervals of several weeks, that lengthen with repeated treatments where the hair regrowth becomes sparser and finer.

The efficacy of certain laser systems at destroying hair follicles within the skin is based on selective photothermolysis. As the melanin absorbs light within its absorption spectrum wavelengths of 600 to 1100 nm, converts it to heat diffusing the energy locally, thermal damage affects the nearby stem cells in the hair bulge and prevents future hair regrowth [5]. Laser systems for that purpose range from the 694-nm Ruby laser at the short end of the spectrum to the 755-nm Alexandrite (Alex) laser, 800- to 810-nm Diode laser in the middle of the spectrum, and the 1064-nm Nd: YAG laser at the end of the spectrum [6,7].

Although several lasers met the wavelength criteria for effecting selective follicular destruction, the treatment of dark skin phototypes is still problematic [2]. The effectiveness of Alex and Nd: YAG laser sources were clinically recognized for photo epilation but still ND-YAG was raised as the safest option for dark skin [6,8].

The Alex laser is a solid-state laser that emits at 755 nm, which allows for a greater depth of penetration, but with more melanin absorption compared to other laser systems. The use of cooling devices allows the laser operator to deliver the effective energy to the dermal target while protecting the epidermis from such thermal injury [9]. To reduce the possible side effects, innovative technologies have been developed. Motus AX Alex laser system has been specially designed and developed with Moveo technology system with both a standard single pass and a Multipass (Moveo) emission method characterized by multiple emissions in the treatment area with low fluences to give an adequate progressive therapeutic dose. Using that innovative handpiece with a cooled sapphire cylinder tip that conveys the laser beam onto the skin drastically reduces system energy leaks to the skin, thus increasing the efficacy of laser transmission. Besides, repeated passes over the small areas cause gradual heating of the vital

parts of the hair giving an adequate progressive therapeutic dose without overheating the skin leading to hair destruction in a painless manner [10,11].

This work aimed to assess the safety and efficacy of the Multipass low fluence, high-frequency 755-nm Alex laser versus high fluence, low-frequency 1064-nm long-pulsed Nd: YAG laser on axillary hair reduction in women with dark skin phototypes.

## **Patients and methods**

### Study design and subjects

This prospective randomized right-left intra-individual study was approved by the Research Ethics Committee (#0190798) of the Faculty of Medicine for Girls, Al-Azhar University. All subjects gave informed written consent before enrollment to participate and to use their photographs for scientific purposes. In all, 30 adult Egyptian women who seek axillary hair removal were recruited from the Outpatient clinic of the University Hospital. These cases were subjected to history taking as well as dermatological examination. Inclusion criteria were age >18 years with Fitzpatrick Skin Type (FST) IV-VI. Exclusion criteria were; pregnancy/lactation, white hairs in the axilla, hirsutism, on oral contraceptive pills, photosensitivity, scar/keloid tendency, systemic diseases, laser hair reduction for axillary or systemic retinoid intake in the previous 6 months, and unrealistic expectations/body dysmorphic disorders.

### Treatment sessions

All patients were randomized by the closed envelope method to receive 5 laser sessions with a 1-month interval. One side was subjected to the high fluence, low frequency long-pulsed 1064-nm ND: YAG laser (Motus AY, DEKA, Florence, Italy) side has treatment settings of 15-20 J/cm<sup>2</sup>, pulse duration 10-20 msec, spot size 16 mm, frequency 1.5 Hz with air cooling. The other side was subjected to the Multipass emission (Moveo handpiece) low fluence, high-frequency 755-nm Alex laser (Motus AY, DEKA, Florence, Italy) side has treatment settings of 5-8 J/cm<sup>2</sup>, pulse duration 3-8 msec, spot size 20 mm, frequency 5 Hz, the total energy emitted 2000J/area of the axilla, with cooled sapphire cylinder tip. The patients were advised to apply topical emollients twice/day following the laser sessions.

## Clinical outcome assessment

Assessment of the response was carried out at the baseline, 1 month and 4 months after the 5th laser session as follows:

- Photographs using Telephoto (I phone 11 plus, USA) with two 12-megapixels cameras, one is a 28mm f1.8 wide-angle lens and the other is a 56mm f22.8 lens by 2 blinded dermatologists.
- Folliscope evaluation (Folliscope 2.8, Lead M, Seoul, Korea) for detecting hair thickness and count in the same fixed square.
- Pain score 1-month post-treatment using a 10-point visual analog pain scale (0 levels as “not painful” and a level of 10 as “worst pain possible”).

## Side effects

All subjects were asked, by 2 blinded dermatologists, about side effects before each session and 1 month after the last laser session and the average was taken, as follows;

- Paradoxical hypertrichosis (0= no hypertrichosis, 1= presence of hypertrichosis).
- Persistent erythema (>48 hours) (using a 3-point scale (0 levels as “no erythema” while the level of 3 as “severe erythema”).
- Post-laser hyperpigmentation (0= no hyperpigmentation, 1= hyperpigmentation).
- Post laser hypopigmentation (0= no hypopigmentation, 1= presence of hypopigmentation).
- White hair (counted in the fixed square).
- Persistent erythema and post-laser hyper/hypopigmentation.

## Statistical analysis

Statistical interpretations were carried out with the SPSS program version 23 (SPSS Inc., Chicago, IL, USA). The appropriate comparisons used the student’s t-test and Chi-square tests.

Correlations between variables were analyzed using Spearman's rank correlation coefficient ( $r$ ).  $P < 0.05$  value was set as statistically significant.

## Results

Overall, the number of cases that completed the study was 23 (11 cases of FST IV, 8 cases of FST V, and 4 cases with FST VI) with a mean age of  $25.8 \pm 3.5$  years (range 20-32 years) and a mean BMI of  $30.7 \pm 4.3$  kg/m<sup>2</sup> (range 23-47.8 kg/m<sup>2</sup>). There was a significant reduction of hair density in both treated sides, being more in the Multipass Alex treated side compared to the long-pulsed Nd: YAG treated side 1 month after the 5th session (Figures 1,2). The same relationships were kept after 4 months after the 5th session but with a lower hair density reduction (Table 1). Besides, the mean hair thickness demonstrated a parallel proportion (Table 2). Overall, there was a significant correlation between hair density/cm<sup>2</sup> and hair thickness (mm) ( $r=0.876$ ;  $p=0.001$ ). By skin type, the mean hair reductions rates in FST IV, V, and VI were significantly higher in the Multipass Alex laser-treated side compared to the Nd: YAG laser-treated side (76.4%, 72.7%, and 70.1% versus 58.9%, 54.0%, and 49.8% respectively). Besides, the visual analog pain scale was significantly lower in the Multipass Alex treated side compared with the long-pulsed YAG treated side (Table 3). The pain was the main reported side effect by the participants being statistically lower in Multipass Alex laser treatment compared with long-pulsed Nd: YAG laser. Besides, one case of FST VI showed hypopigmentation at Multipass Alex laser treated side 1 month after the 5th session. Another case of FST VI showed hyperpigmentation on both treated sides. Both cases were resolved during the follow-up period.

## Discussion

Laser hair removal is a widely used treatment for unwanted hair. Hence, good knowledge of hair follicle anatomy and physiology, proper patient selection and principles of laser safety, familiarity with the various laser devices, and an in-depth understanding of laser-tissue interactions are essential for optimizing treatment efficacy while diminishing complications and adverse effects, especially in the dark-skinned cases.

In the current study, the percentage of hair density reduction showed significant improvement 1 month after the 5th laser session in both long-pulsed Nd: YAG laser, as well as Multipass Alex laser, treated sides compared to the baseline being more in the Multipass Alex laser-treated side

with parallel significant decreases in hair thickness. The same relationship was demonstrated 4 months of follow up but with lower improvements.

Several researchers pointed out that the 1064-nm Nd: YAG laser has an impressive reduction in hair regrowth in individuals with dark skin [12-15]. Besides, the effectiveness of hair removal with the long-pulsed 755-nm Alex laser was first described by Finkel et al. [16]. In their study, Aldraibi et al. [16] postulated that the long-pulse 755-nm Alex laser spectrum is high enough on the spectrum of melanin light absorption to be considered appropriate for darker skin types. These authors studied a 3-ms Alex laser in 31 patients (FST IV-VI) that received either an 18-mm or 15-mm spot size; fluence range 8 to 32 J/cm<sup>2</sup>. The mean hair reduction was 36% at 6 months. By skin type, the mean hair reductions were 29%, 33.6%, and 48.6% in FST IV, V, and VI respectively. At 1-week post-treatment, hyperpigmentation was noted in 48.4% of the subjects; however, by 6 months, only one patient with FST VI still displayed mild hyperpigmentation. Also, at 1 week, 8 sites showed crusting, 7 of which proceeded to hypopigmentation. Therefore, these authors concluded that the results was satisfying in dark skin by the long pulse 755 Alex laser but with some side effects.

Besides, Nisticò et al. [10] evaluated the safety and efficacy of the long-pulsed 755-nm Alex laser equipped with Moveo handpiece on 49 patients, skin types II to IV. The treated areas included the face, limbs, groins, and axillae. All the patients completed 4 sessions at 4-6 weeks interval. A marked reduction in hair regrowth was noted 3 months after the final treatment in all body locations where axillary hair demonstrated the most impressive hair reduction scores (>90%). Additionally, Nisticò et al. [17] performed a prospective, pilot study on 16 patients (15 females, 1 male, FST IV to VI) with unwanted hair on the different body areas. All patients were treated with long-pulsed 755-nm Alex laser, equipped with a special handpiece with a cooled sapphire cylinder tip 4 treatments with 4- to 6-week intervals were executed with a final evaluation done at 3 months after their last treatment. These patients experienced a marked reduction in the unwanted hair in the axillary and inguinal zone, with a mean reduction of hair up to 90%. Minor side effects were noted; 7 patients experienced erythema and discomfort after the sessions that lasted 3-4 days before disappearing.

Inline, Bonan et al. [11] carried out a randomized split-body controlled study on body hair removal comparing the standard single pass (SP) emission with the Multipass emission (Moveo



handpiece) with 755-nm Alex laser. Overall, 108 patients, of whom 96 were female, with FST I to VI underwent laser hair removal, by treating one side of the body using the standard SP and the other one with the Moveo including face, arms, legs, trunk, axillae, and groins. Each patient underwent 3-8 treatment sessions every 6 weeks, with a 6-month follow-up. The mean overall hair reduction rate was 87.0% for standard SP and 78.5% for Moveo with no significant differences. The pain was significantly higher after standard SP than after Moveo treatment (4.2 vs 1.5). The patients were satisfied with both treatments, reporting a preference for Moveo (84% vs 16%). These researchers concluded that standard SP and Moveo 755-nm Alex laser is effective and safe for hair removal in all FSTs where Moveo has a higher security profile with lesser side effects.

Previously, some side effects have been reported due to Alex laser use including purpura, paradoxical hypertrichosis, dry skin, allergic/chemical skin reaction, accelerated skin aging, induction or aggravation of acne, rosacea-like rash [18-20]. However, in the current study, the pain was the main reported side effect by the participants being statistically lower after Multipass Alex laser treatment compared with long-pulsed Nd: YAG laser.

Still, the current study has some limitations such as the relatively low number of participated cases, assessment of the results on lighter skin types, and the need to increase the number of sessions and the follow-up periods.

## **Conclusion**

From the aforementioned results, it could be concluded that the Multipass low fluence, high-frequency 755-nm Alex laser technique is safe and effective for hair removal in darker phototypes Compared to the high fluence, low frequency 1064-nm long pulsed Nd:YAG laser.

## References

1. Alizadeh N, Ayyoubi S, Naghipour M, Hassanzadeh R, Mohtasham-Amiri Z, Zaresharifi S, Gharaei Nejad K. Can laser treatment improve quality of life of hirsute women?. *Int J Womens Health*. 2017; 9:777-780.
2. Li W, Liu C, Chen Z, Cai L, Zhou C, Xu Q, Li H, Zhang J. Safety and efficacy of low fluence, high repetition rate versus high fluence, low repetition rate 810-nm diode laser for axillary hair removal in Chinese women. *J Cosmet Laser Ther*. 2016; 18:393-396.
3. Zandi S, Lui H. Long-term removal of unwanted hair using light. *Dermatol Clin*. 2013; 31: 179-191.
4. Fazel Z, Majidpour A, Behrangi E, Fathizadeh S, Nokandeh M, Atefi N, Ghassemi MR. using the hair removal laser in the axillary region and its effect on normal microbial flora. *J Lasers Med Sci*. 2020; 11:255-261.
5. Haedersdal M, Beerwerth F, Nash JF. Laser and intense pulsed light hair removal technologies: from professional to home use. *Br J Dermatol*. 2011; 165 (Suppl 3):31-6.
6. Gan SD, Graber EM. Laser hair removal: a review. *Dermatol Surg*. 2013; 39:823-838.
7. Mohamed EE, Ahmed AM, Tawfik KM, Ibrahim SM. Trichoscopic changes in hair during treatment of hirsutism with 1064-nm neodymium:yttrium-aluminum-garnet laser. *J Cosmet Dermatol*. 2016; 15:31-35.
8. Alavi S, Abolhasani E, Nilforoushzadeh M. Effects of hair removal alexandrite laser on biometric parameters of the skin. *Lasers Med Sci*. 2016; 31:481-484.
9. Aleem S, Majid I. Unconventional uses of laser hair removal: A review. *J Cutan Aesthet Surg*. 2019; 12:8-16.
10. Nistico SP, Del Duca E, Farnetani F, Guida S, Pellacani G, Rajabi-Estarabadi A, Nouri K. Removal of unwanted hair: efficacy, tolerability, and safety of long-pulsed 755-nm alexandrite laser equipped with a sapphire handpiece. *Lasers Med Sci*. 2018; 33:1479-1483.

11. Bonan P, Michela Troiano M, Verdelli A. Safety and efficacy of single pass vs multipass emission with 755 alexandrite laser for all-skin-type hair removal: A pilot study. *Dermatologic Therapy*. 2020; e14001.
12. Ismail SA. Long-pulsed Nd: YAG laser vs. intense pulsed light for hair removal in dark skin: a randomized controlled trial. *Br J Dermatol*. 2012; 166:317-321.
13. Vachiramon V, Brown T, McMichael AJ. Patient satisfaction and complications following laser hair removal in ethnic skin. *J Drugs Dermatol*. 2012; 11:191-195.
14. Chan CS, Dover JS. Nd: YAG laser hair removal in Fitzpatrick skin types IV to VI. *J Drugs Dermatol*. 2013; 12:366-367.
15. Bibilash Bs, Chittoria RK, Thappa DM, Mohapatra DP, Friji Mt, Dineshkumar S, Pandey S. Are lasers superior to lights in the photoepilation of Fitzpatrick V and VI skin types? - A comparison between Nd: YAG laser and intense pulsed light *J Cosmet Laser Ther*. 2017; 19: 252-255.
16. Aldraibi MS, Touma DJ, Khachemoune A. Hair removal with the 3- msec alexandrite laser in patients with skin types IV-VI: efficacy, safety, and the role of topical corticosteroids in preventing side effects. *J Drugs Dermatol*. 2007; 6:60–66.
17. Finkel B, Eliezri YD, Waldman A, Slatkine M. Pulsed alexandrite laser technology for noninvasive hair removal. *J Clin Laser Med Surg*. 1997; 15:225-229.
18. Nistico SP, Bennardo L, Del Duca E, Tamburi F, Ali Rajabi-Estarabadi 4 , Keyvan Nouri K. Long-pulsed 755-nm alexandrite laser equipped with a sapphire handpiece: unwanted hair removal in darker phototypes. *Lasers Med Sci*. 2021; 36:237-238.
19. Rasheed AI. Uncommonly reported side effects of hair removal by long pulsed-alexandrite laser. *J Cosmet Dermatol*. 2009; 8:267-274.
20. Al-Hargan A, Ghobara YA, Al-Issa A. Purpura induced by laser hair removal: a case report. *J Med Case Rep*. 2018; 12:60.

## Legends

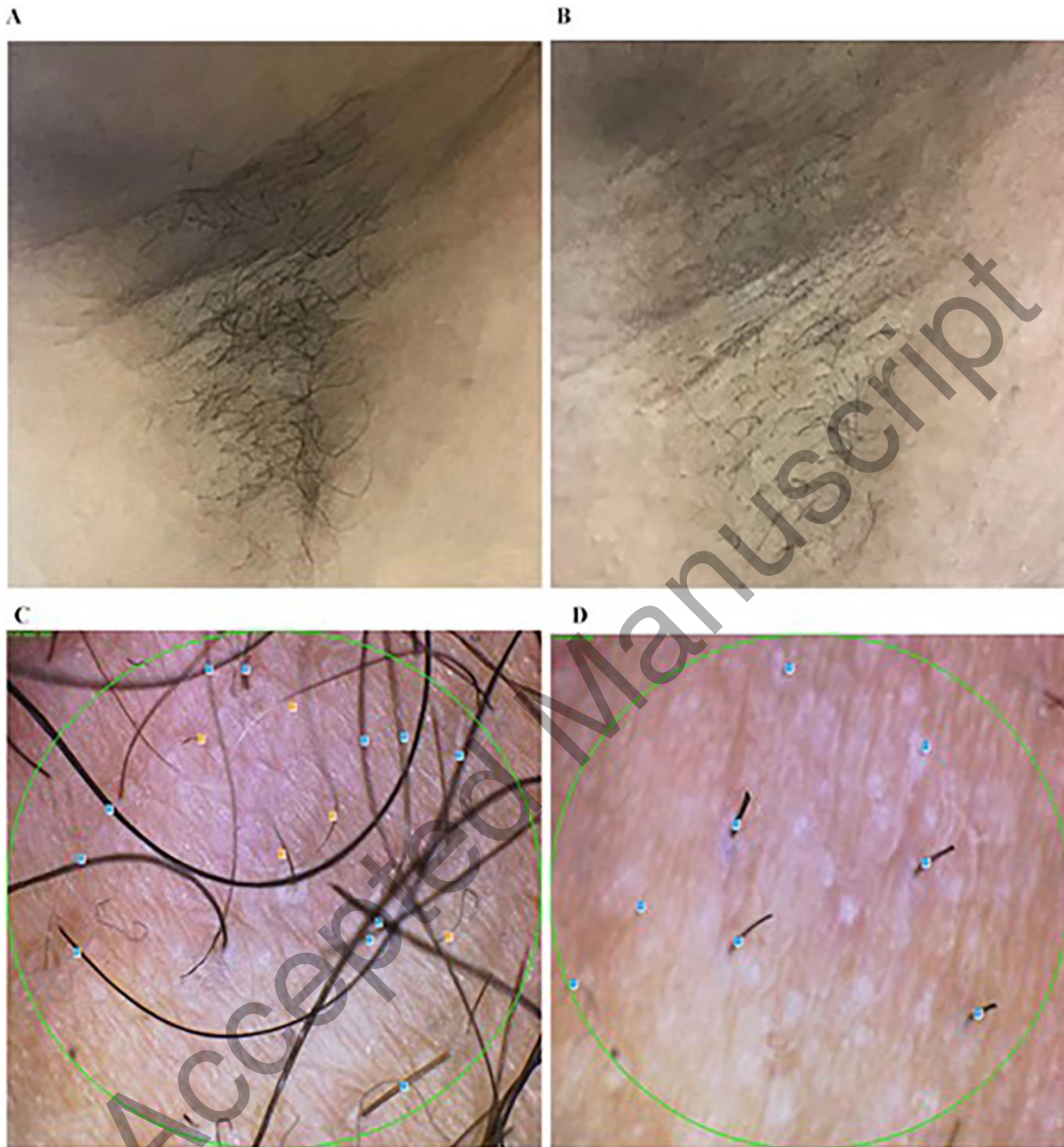


Figure 1. Female patient aged 20 years. Long-pulsed Nd: YAG treated side. The clinical picture at baseline (A) and 1 month after the 5th laser session (B). Dermoscopy picture at baseline (C) and 1 month after the 5th laser session (D).

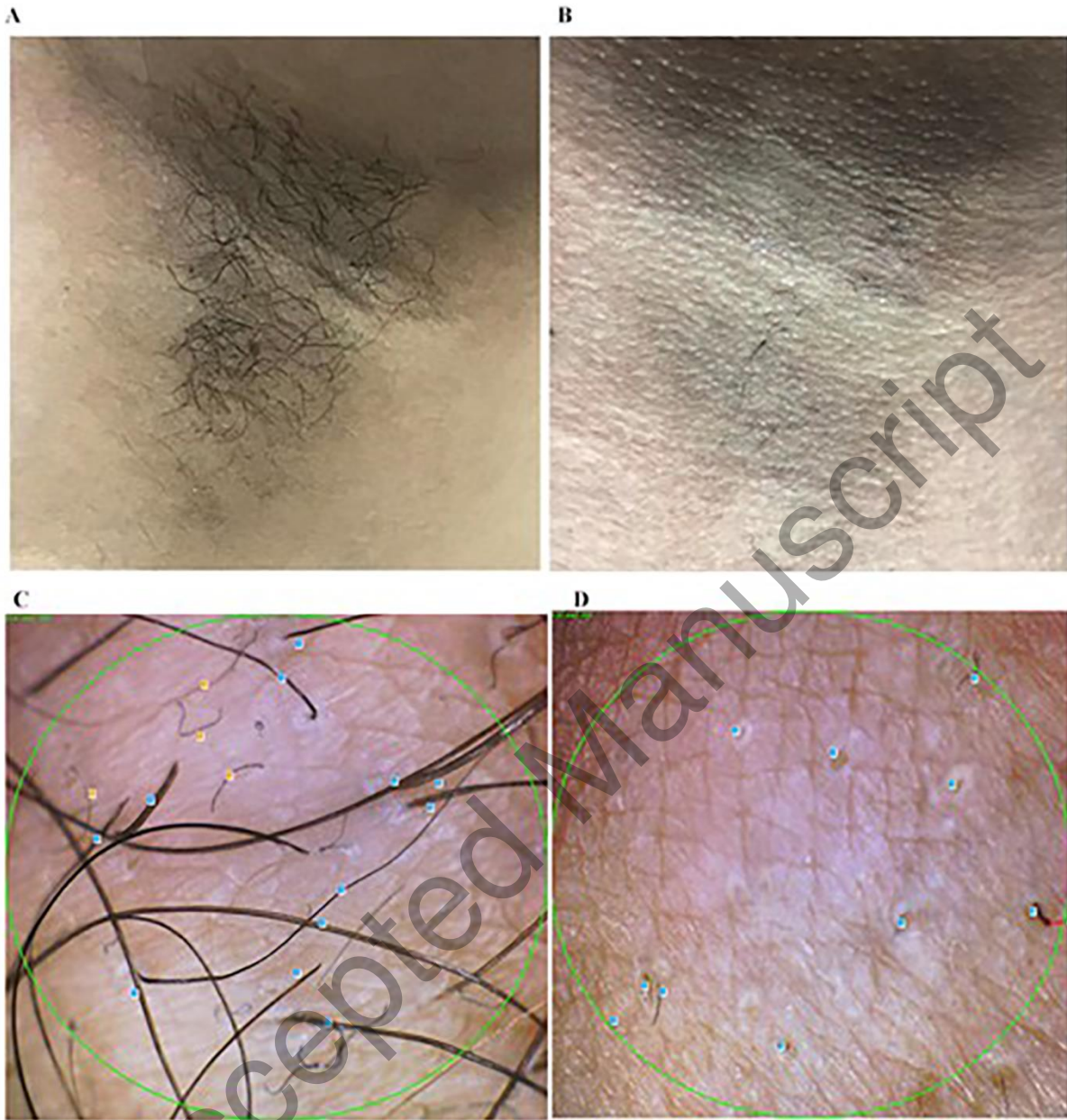

Figure 2. Female patient aged 20 years (the same patient). Multipass Alex laser-treated side. The clinical picture at baseline (A) and 1 month after the 5th laser session (B). Dermoscopy picture at baseline (C) and 1 months after the 5th laser session (D).

**Table 1. Data of hair density (cm<sup>2</sup>) in treated cases (mean ± SD, range)**

	<b>Nd: YAG treated side</b>	<b>Multipass Alex treated side</b>	<b>P</b>
Baseline	29.1 ± 5.9 (19-39)	29.8 ± 7.0 (20-45)	0.786
<b>1 month after the 5<sup>th</sup> session<sup>#</sup></b>	12.2 ± 2.6 (8-16)	7.4 ± 1.8 (5-12)	0.001*
Decline rate (%) <sup>##</sup>	58.0 ± 2.1 (54.2-61.5)	75.2 ± 1.9 (72.2-80)	0.001*
<b>4 months after the 5<sup>th</sup> session<sup>#</sup></b>	17.7 ± 4.3 (10-25)	13.7 ± 3.6 (8-21)	0.001*
Decline rate (%) <sup>##</sup>	39.0 ± 2.5 (35.7-45)	54.6 ± 2.3 (51.2-60.0)	0.001*

\*P&lt;0.05 is considered statistically significant

<sup>#</sup>Student's t test.<sup>##</sup>Chi square t test.**Table 2. Comparison of hair thickness in treated cases (mm) (mean ± SD, range)**

	<b>Nd: YAG treated side</b>	<b>Multipass Alex treated side</b>	<b>P</b>
<b>Baseline</b>	0.075 ± 0.009 (0.047-0.088)	0.071 ± 0.009 (0.045-0.080)	0.139
<b>1 month after the 5<sup>th</sup> session<sup>#</sup></b>	0.041 ± 0.005 (0.027-0.047)	0.030 ± 0.004 (0.025-0.044)	0.001*
Variation <sup>#</sup>	0.034 ± 0.007 (0.017-0.054)	0.040 ± 0.007 (0.020-0.050)	0.006*
Decline (%) <sup>##</sup>	45.2 ± 5.1 (35.9-63.5)	57.3 ± 5.4 (42.1-63.0)	0.001*
<b>4 month after the 5<sup>th</sup> session<sup>#</sup></b>	0.042 ± 0.004 (0.028-0.048)	0.031 ± 0.004 (0.025-0.045)	0.001*
Variation <sup>#</sup>	0.033 ± 0.005 (0.019-0.041)	0.039 ± 0.007 (0.020-0.049)	0.002*
Decline (%) <sup>##</sup>	43.6 ± 3.2 (36.2-49.4)	55.9 ± 5.1 (40.7-62.7)	0.001*

\*P&lt;0.05 is considered statistically significant

<sup>#</sup>Student's t test.<sup>##</sup>Chi square t test.**Table 3. Comparison of visual analog pain score in the treated cases (mean ± SD)**

	<b>Nd: YAG treated side</b>	<b>Multipass Alex treated side</b>	<b>P</b>
<b>Pain score</b>	4.52 ± 0.51	2.61 ± 0.50	0.001*

\*Statistical significant difference

<sup>#</sup>Student's t test

Accepted Manuscript