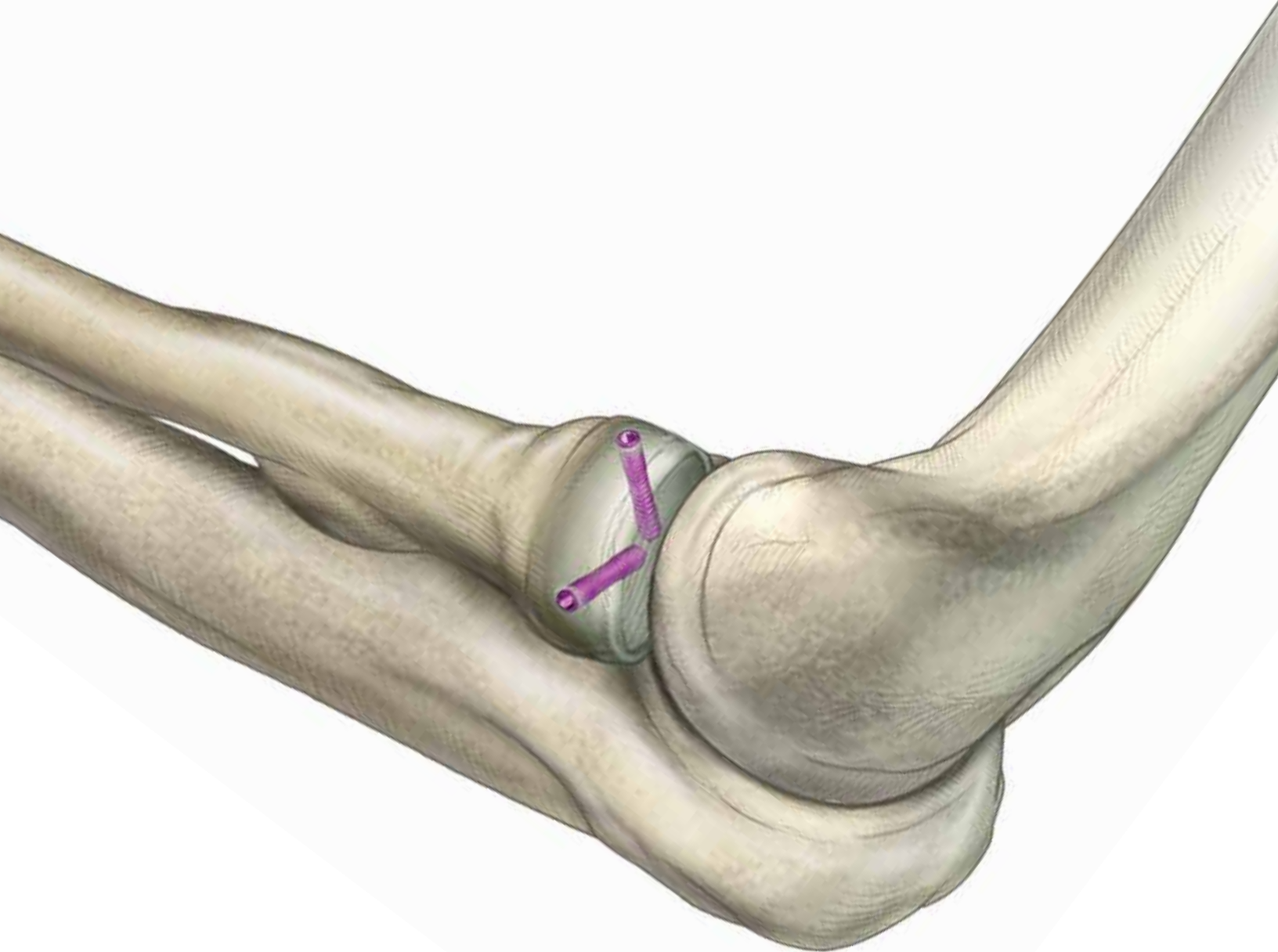


Case Study: Radial Head Fracture

Treated with Acutrak 2® Micro Screws



INDICATION: Acute Right Radial Head Fracture

PRODUCTS: Acutrak 2® Micro Screws

SURGEON: Richard S. Moore, MD

PATIENT HISTORY

The patient is a 64-year-old right hand dominant female who presented to the ER following a mechanical fall onto an outstretched right hand. She complained of pain and limited range of motion of the elbow. AP, lateral and oblique X-rays were obtained confirming a displaced radial head fracture. The elbow was located and the patient's neurovascular exam was normal. She was splinted and outpatient follow-up was arranged.

The patient was seen in follow-up and the X-rays were reviewed. She was noted to have a displaced radial head fracture with a large depressed articular fragment involving approximately 50% of the radial head. A CT scan was obtained defining the fracture pattern and confirming an intact "radial pillar". The fracture was felt to be amenable to ORIF and optimally managed with Acutrak 2® screws.

TREATMENT

The patient was taken to the operating room and positioned supine. A lateral approach was utilized with an arthrotomy anterior to the lateral ligamentous complex preserving its integrity. There was a capitellar articular sheer fragment incarcerated in the fracture

site which was removed and excised. The fracture was reduced by elevation of the fragment taking care to preserve the periosteal sleeve and vascularity. Provisional fixation was achieved with guide wires and reduction confirmed under direct visualization and fluoroscopy. The Acutrak 2® Micro screws were then placed in standard fashion and final static and dynamic fluoroscopic images obtained. There was full range of motion without instability on the table. A standard layered closure was carried out taking care to reef the lateral ligaments.

POSTOPERATIVE RESULTS

Postoperatively early active range of motion was initiated and the patient progressed to clinical and radiographic union. At six months she had achieved near full range of motion with a flexion contracture of 5° and full flexion, supination and pronation. She had returned to full unrestricted activity with minimal complaints of pain despite the known capitellar chondral injury and was very pleased with her functional and symptomatic result.

*The information found within this material contains the opinion of a medical professional. Compensation was made to the consulting medical professional for the creation of this case series.

FIGURE 1: Preoperative X-ray

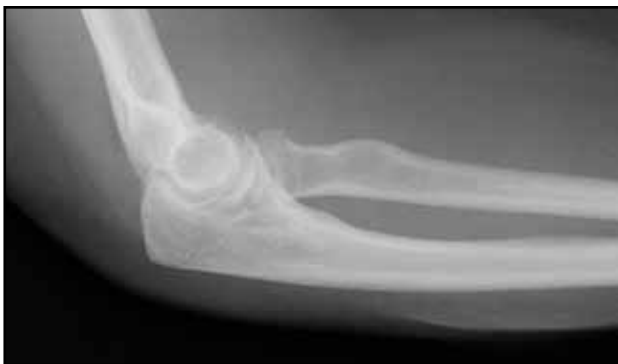

FIGURE 2: Postoperative X-ray

