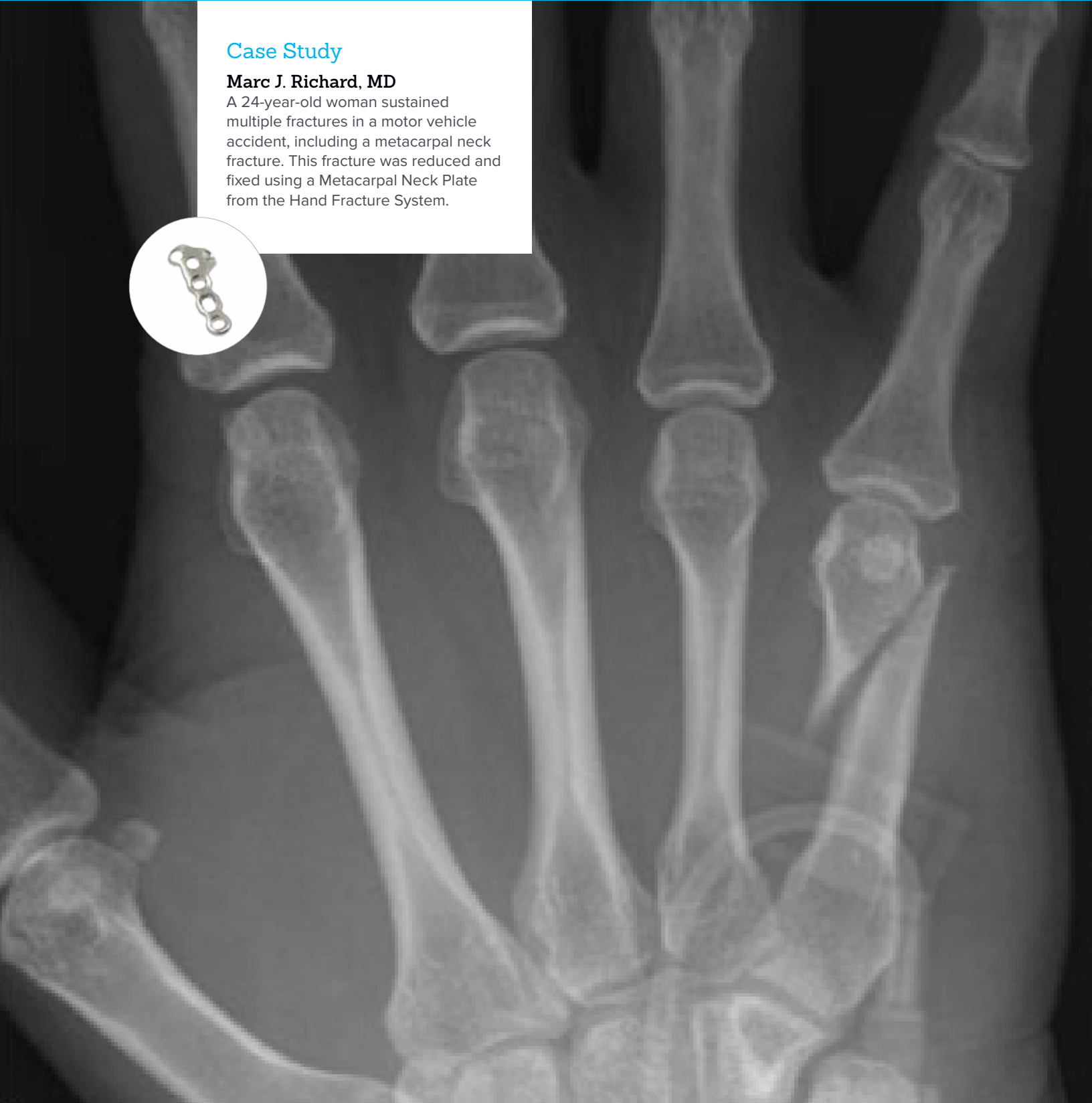


## Open Reduction & Internal Fixation of a Fifth Metacarpal Neck Fracture

### Case Study

**Marc J. Richard, MD**

A 24-year-old woman sustained multiple fractures in a motor vehicle accident, including a metacarpal neck fracture. This fracture was reduced and fixed using a Metacarpal Neck Plate from the Hand Fracture System.



Acumed® is a global leader of innovative orthopaedic and medical solutions.



We are dedicated to developing products, service methods, and approaches that improve patient care.

## Case Study | Marc J. Richard, MD

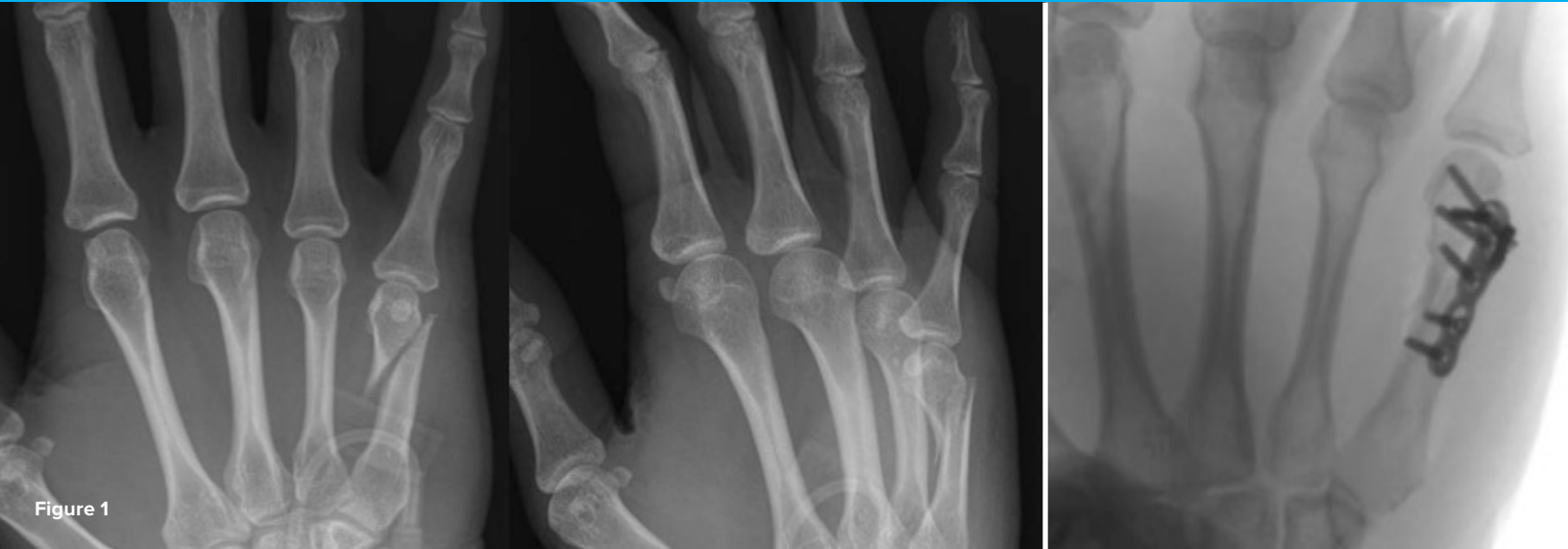

Figure 1

## Open Reduction & Internal Fixation of a Fifth Metacarpal Neck Fracture

### Patient History

A 24-year-old, right-hand-dominant woman sustained multiple fractures in a motor vehicle collision. Her injuries included a right fifth metacarpal neck fracture, contralateral distal radius and open distal humerus fractures, and an acetabular fracture. Radiographs of her right hand demonstrated a fracture of the metacarpal neck with approximately 20 degrees of apex dorsal angulation and 4 mm of shortening (Figure 1). There was no significant comminution. On physical exam, she had limited flexion and extension secondary to the injury, but she had no evidence of rotational deformity. Closed reduction of the fifth metacarpal neck fracture was performed at the time of her original presentation and a short-arm ulnar gutter splint in intrinsic plus position was applied. Given her multiple injuries, open reduction and internal fixation was selected for all fractures to facilitate her rehabilitation (figures 2a & 2b). The fifth metacarpal neck fracture was fixed definitively at the time of her distal radius fracture repair.

## Treatment

The patient was taken to the operating room and was placed supine on the operating table with a hand table attachment. After fixation of the contralateral distal radius fracture, attention was turned to the fifth metacarpal neck fracture. A longitudinal incision was made along the long axis of the fifth metacarpal. This incision was purposefully made to not be in line with the underlying extensor tendons. The extensor tendons were retracted radially and the dorsal aspect of the metacarpal and interosseous muscles were revealed. A Beaver blade was used to sharply incise the periosteum on the ulnar aspect of the dorsal metacarpal and full thickness flaps were carefully raised. These flaps of periosteum and interosseous fascia were preserved for coverage of the plate during closure. The fracture site was exposed and debrided of fracture hematoma. Provisional reduction was achieved with an obliquely oriented, .045" K-wire from distal to proximal through the radial collateral recess. The 1.3 mm Metacarpal Neck Plate from the Acumed Hand Fracture System was selected and was applied on the dorsal-ulnar aspect of the metacarpal. The plate was provisionally fixed with bone reduction forceps distally and a plate tack in the proximal hole. A 2.3 mm Acumed Hexalobe Lag Screw was then placed through the oblong hole and C-arm fluoroscopy was used to confirm proper plate placement. A slightly supinated lateral view of the hand is helpful for viewing the sagittal alignment of the fifth metacarpal. The distal-most screws were placed using 1.5 mm Acumed Hexalobe MultiScrews and the C-arm was again used to confirm position within the metacarpal head. The digits were examined to confirm appropriate rotational alignment with all fingertips pointing to the distal pole of the scaphoid and no overlap. With appropriate reduction and plate position confirmed, the remaining shaft screws were placed using 2.3 mm Hexalobe MultiScrews in locked fashion (Figure 3). The periosteum and fascia were easily closed over the plate with interrupted absorbable sutures to preserve a gliding layer for the tendons above the plate. The skin was closed with interrupted nylon sutures.

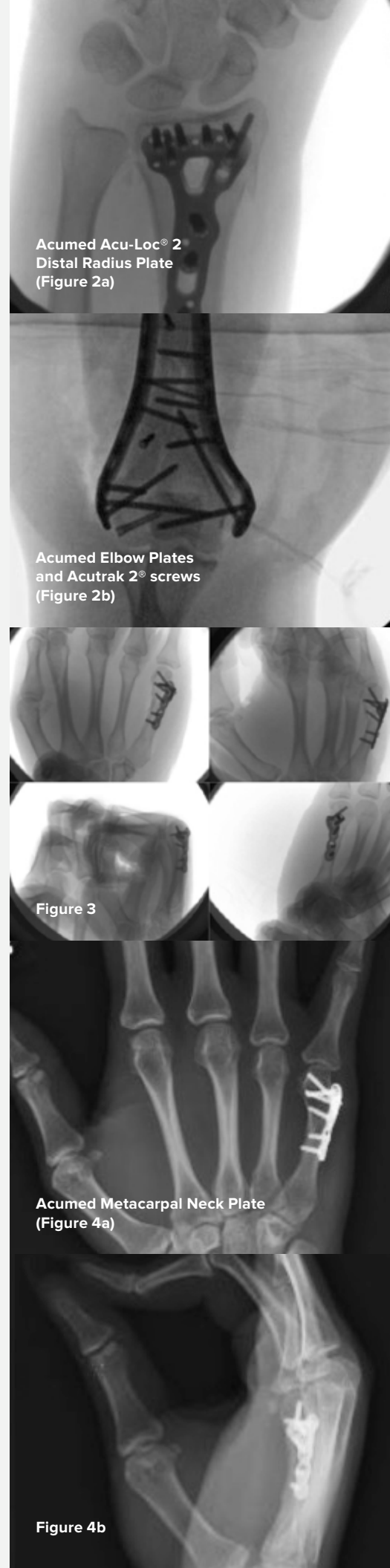
## Postoperative Care

The patient was placed into a wrist splint that was later converted to a short arm cast to allow platform weight-bearing through the forearm with her concomitant injuries. If this was an isolated injury, she would have been placed into a removable wrist splint for comfort and initiated immediate finger range of motion. Even in the short arm cast, her fingers were free and she began range of motion immediately post-op. She was evaluated clinically and radiographically at 2, 6, and 12 weeks post-op and united by 12 weeks (figures 4a & 4b). She was able to regain range of motion of the small finger to 90 degrees of MCP flexion, 95 degrees of PIP flexion, and 45 degrees of DIP flexion.

## Discussion

Extra-articular fifth metacarpal neck fractures are common injuries. The fifth metacarpal has the greatest tolerance for angulation of the metacarpals. However, careful attention must be paid to the specific fracture characteristics and patient factors that may benefit from operative fixation. Rotational malalignment must be assessed and if present, is an indication for operative management. Shortening and angulation are also relative indications for fixation and are directly related: the greater the angulation, the greater the shortening. In general, there is less tolerance for angulation with a more proximal fracture site.

Fracture patterns with oblique orientation, shortening and angulation (as seen here) are unstable and benefit from open reduction and internal fixation. The Metacarpal Neck Plate allows the surgeon to place the hardware more laterally to help minimize plate contact with extensor tendons. The plate is also designed to sit proximally with the distal screws angled distally. The plate does not overlie the collateral ligaments, which is intended to facilitate postoperative rehabilitation.





**HNW70-20-B**

Effective: 2017/09

© 2017 Acumed® LLC

Acumed® Headquarters  
5885 NW Cornelius Pass Road  
Hillsboro, OR 97124  
Office: 888.627.9957  
Fax: 503.520.9618  
[www.acumed.net](http://www.acumed.net)

These materials contain information about products that may or may not be available in any particular country or may be available under different trademarks in different countries. The products may be approved or cleared by governmental regulatory organizations for sale or use with different indications or restrictions in different countries. Products may not be approved for use in all countries. Nothing contained on these materials should be construed as a promotion or solicitation for any product or for the use of any product in a particular way which is not authorized under the laws and regulations of the country where the reader is located. Specific questions physicians may have about the availability and use of the products described on these materials should be directed to their particular authorized Acumed distributor. Specific questions patients may have about the use of the products described in these materials or the appropriateness for their own conditions should be directed to their own physician.

